

An Unusual Case of Renal Infection with *Mycobacterium senegalense*

JENNIFER MARIA SELVAKANI¹, PRIYADARSHINI SHANMUGAM²,
R ALICE PEACE SELVABAI³, VIGNESHWARAN JAYASEKARAN⁴



ABSTRACT

Mycobacterium senegalense is a Non Tuberculous Mycobacteria (NTM) belonging to rapid growers *Mycobacterium fortuitum* group. Authors describe a unique case of *Mycobacterium senegalense* infection in a 62-year-old diabetic male with bilateral pyelonephritis and acute kidney injury, as patient had complaints of haematuria on and off for a week. *Mycobacterium senegalense* is difficult to diagnose as the symptoms are expansive and routine diagnostic tests have lesser sensitivity. It remains resistant to the commonly used antibiotics. The patient was under multiple antibiotic regimens for a long period of time and the isolate grown from the urine sample was identified by Matrix Assisted Laser Desorption Ionisation- Time of Flight (MALDI-TOF) as *Mycobacterium senegalense*. Later, the patient was started on antitubercular therapy and finally responded.

Keywords: Acute kidney injury, Non tuberculous mycobacteria, Rapid growers

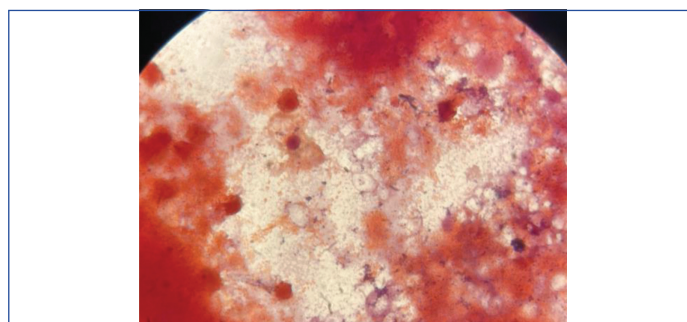
CASE REPORT

A 62-year-old gentleman was brought to the General Medicine department with complaints of loss of weight and appetite, polyuria, dysuria, haematuria, fatigue, evening rise in temperature, abdominal pain in right hypochondriac region and constipation for four days. On examination patient was conscious, well oriented, febrile, had pallor and bilateral mild pitting pedal oedema.

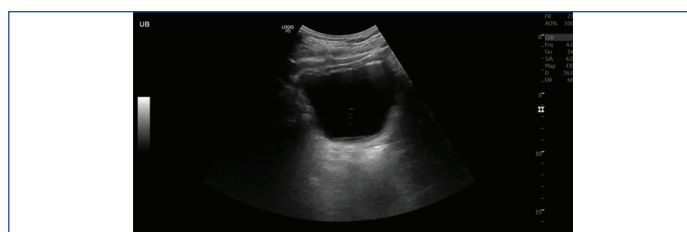He was a known diabetic for 15 years on strict diabetic diet, recently diagnosed with Parkinson's disease a year ago and on syndopa 110 mg. In 2014, patient developed plantar fasciitis in right heel due to atheromatous changes in all major arteries of right lower limb with mild stenosis at multiple levels. Patient has been chronically dysuric for which he had been admitted multiple times and been prescribed various antibiotics such as tablet doxycycline and levofloxacin. The patient also had coronary artery disease, moderate left ventricular dysfunction and an old inferior wall myocardial infarction hence on Atorvas 20 mg and Cardivas 12.5 mg. He also gave a history of bilateral pyelonephritis with acute kidney injury. He had suffered from acute lacunar infarct in left thalamus and was currently on Aspirin 75 mg. The patient had been following the above-mentioned treatment protocol for the past three years. In early 2021, patient developed a progressive non healing skin ulcer in the right foot on the lateral aspect and the lesion was debrided. He was a non smoker, non alcoholic and consumed a mixed diet with normal sleep and bowel habits.

On further examination, Gram stain of the urine sample revealed plenty of pus cells and Gram-negative bacilli [Table/Fig-1]. Urine was positive for albumin and leucocytes esterase. Haemoglobin was 8.5 g/dL; blood urea nitrogen and serum creatinine were elevated at 30 mg/dL and 3.53 mg/dL, respectively. Alanine Transaminase (ALT) (153 U/L), Aspartate Aminotransferase AST (225 U/L) gamma glutamyl transferase (165 U/L) were mildly elevated. Alkaline phosphatase and electrolytes were normal. His glycaemic control was poor. Ultrasound examination of the abdomen revealed bladder wall thickening with layered echogenic debris suggesting cystitis [Table/Fig-2]. He also had multiple renal calculi in the right kidney, the largest measuring 10 mm.

Blood culture yielded methicillin resistant *Staphylococcus epidermidis* and urine sample inoculated in Cysteine Lactose Electrolyte Deficient Medium (CLED) media yielded significant growth of *Escherichia coli* with a colony count of more than 10^5 cfu/ml.

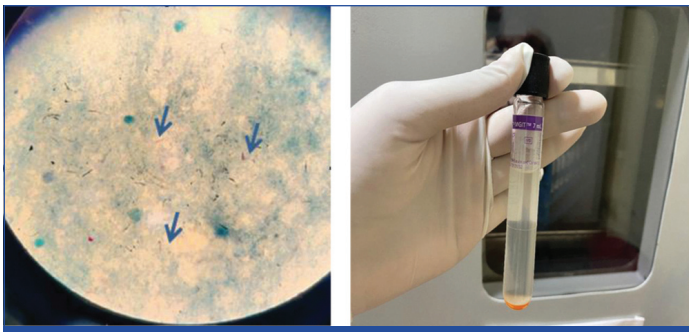


[Table/Fig-1]: Urine gram stain (100x magnification) showing gram negative bacilli and pus cells.



[Table/Fig-2]: USG of KUB showing thickened bladder measuring 5.1 mm suggestive of cystitis.

In view of multiple co-morbidities and repeated similar symptomatic episodes in the past; urine for Acid Fast Bacilli (AFB) was suggested. Urine acid fast staining revealed the presence of AFB [Table/Fig-3]. The sample was negative for *Mycobacterium tuberculosis* by Gene Xpert. Simultaneously, the sample was inoculated into Mycobacterial Growth Indicator Tube (MGIT) and Lowenstein Jensen medium. MGIT medium flagged positive within 21 days [Table/Fig-4]. The AFB staining from the MGIT medium demonstrated the presence of scanty AFB. Lowenstein Jensen medium yielded light yellow-coloured colonies in 20 days. Further the growth from MGIT was subjected to Matrix-Assisted Laser Desorption/Ionisation- Time of Flight (MALDI-ToF) method and was diagnosed as *Mycobacterium senegalense*. Repeat urine samples collected from the patient also yielded the same organism. Hence, he was started on antitubercular therapy for a period of six months. After three months of therapy the patient improved clinically with normal micturition and his blood urea nitrogen and creatinine dropped to 24 mg/dL and 2.48 mg/dL, respectively. Patient was treated with clarithromycin (500 mg twice



[Table/Fig-3]: Acid Fast Bacilli (AFB) seen in 100X magnification.

[Table/Fig-4]: MGIT culture. (Images from left to right)

daily), rifampicin (450 mg once a day) and ethambutol (1000 mg once a day on alternate days). The duration of the planned treatment was for six months. After five months of chemotherapy, the patient's urine became negative for AFB and his urea and creatinine reduced. Patient clinically improved, as evidenced by weight gain, return of good appetite with normal micturition. The patient's blood counts and renal parameters returned to normal.

DISCUSSION

The NTM comprises those mycobacteria which do not belong to the *Mycobacteria tuberculosis* complex. Currently, 140 species of NTM have been recognised [1]. NTM that grow in a period of less than seven days are referred to as rapid growers. The rapid growing mycobacteria are potentially pathogenic, causing disease in both immune-competent and immune-compromised patients. Like most of NTM, these organisms are ubiquitous in the environment and are present worldwide. They are found in soil, municipal water supplies, backwoods, in marine and terrestrial life forms. *Mycobacterium senegalense*, part of *Mycobacterium fortuitum* group of rapidly growing Mycobacteria was first described by Chamoiseau in 1973 (ATCC 35796); it was discovered as subspecies of *Mycobacterium farcinogenes* later described as distinct species that is closely related to *Mycobacterium farcinogenes* [2]. The bovine farcy, a chronic granulomatous disease of the skin of zebu cattle is caused by *Mycobacterium farcinogenes* and *Mycobacterium senegalense* [3]. Only a small number of reports provide evidence that *Mycobacterium senegalense* cause human infections. As per the literature, *Mycobacterium senegalense* are reported scarcely in India. A 49-year-old female with non Hodgkin's lymphoma was the earliest case of human infection by *Mycobacterium senegalense* which was stated in 2005 [2]. In 2020 Niyas VK et al., reported a case of umbilical port-site infection caused by *Mycobacterium senegalense* [4].

Mycobacterium senegalense stains weakly Gram positive in Gram stain resembling diphtheroids. Its cell wall contains mycolic acids, 2-alkyl 3-hydroxy long-chain fatty acids, that can be separated into α' , α , and epoxy mycolates [5]. Route of entry is through skin, subcutaneous tissue due to trauma, injection, or surgery and it can also spread by contact with animals. This patient in this case had HbA1C level of 9.8% in early 2021 suggesting immunocompromised

state and further he developed non healing progressive ulcer due to atheromatic changes in peripheral blood vessel; this could have been a point of entry of this organism into the blood stream.

It is acknowledged that *Mycobacterium fortuitum* (complex) induces an extensive range of infections involving various wounds, infection of lung and catheters. *M. senegalense* causes bloodstream, wound, and airway infections [3].

Since there are lesser known facts about *Mycobacterium senegalense*, we take the clinical manifestation of *Mycobacterium fortuitum* group into consideration that it causes non cavitary pneumonia, keratitis, endocarditis, lymphadenitis, osteomyelitis, and skin infections [6]. The cutaneous lesions demonstrate papulopustular lesions to sinuses and ulcers, with extensive subcutaneous necrosis and serosanguineous or purulent discharge. Cellulitis and abscess formation are common. Few patients develop lymphocutaneous (sporotrichoid) spread or satellite abscesses [5]. Considering the clinical manifestations of this organism, the organism could have spread through the haematogenous route.

In this case, the blood sample of the patient yielded methicillin resistant *Staphylococcus epidermidis* which further reiterates that the patient may have been immunocompromised due to chronic hyperglycaemic state. Traditionally, a combination of drugs is administered to avoid resistance to monotherapy [7]. In this case, patient was treated with clarithromycin, rifampicin and ethambutol.

CONCLUSION(S)

With the limited knowledge of this species, authors observed that it affects immunocompetent and immunocompromised individuals and this organism should be considered as a threat rather than a benign environmental organism. Early diagnosis of this organism is essential as this can prevent use of unnecessary antibiotics and multiple hospital admissions and disease related complications. Care should be taken to consider the age and co-morbidities of the patient as in this case patient was an elderly and had kidney injury. Authors present this case to further add to the sparse body of literature on this organism and create awareness.

REFERENCES

- [1] MLA. Tille, Patricia M., author. Bailey & Scott's Diagnostic Microbiology. St. Louis, Missouri: Elsevier, 2014. APA. Tille, Patricia M., author. (2014).
- [2] Oh WS, Ko KS, Song JH, Lee MY, Ryu SY, Heo S, et al. Catheter-associated bacteremia by *Mycobacterium senegalense* in Korea. BMC Infectious Diseases. 2005;5(1):01-05.
- [3] Han XY, Dé I, Jacobson KL. Rapidly growing mycobacteria: Clinical and microbiologic studies of 115 cases. Am J Clin Pathol. 2007;128(4):612-21.
- [4] Niyas VK, Keri VC, Singh BK, Kumar P. Persistent laparoscopic port-site discharging sinus: A rare case of *Mycobacterium senegalense* infection. Int J Mycobacteriology. 2020;9(1):100.
- [5] Aghajani J, Rajaei E, Farnia P, Malekshahian D, Seif S. *Mycobacterium farcinogenes* and *Mycobacterium senegalense* as new environmental threats. Biomed and Biotech Res J. 2018;2(3):184.
- [6] Atlas of Dermatology, Dermatopathology and Venereology Cutaneous Mycobacterial Infections Ramya Vangipuram, Stephen K. Tying. Springer Science and Business Media LLC, 2022. Edition 1. Pg 23-35. <https://doi.org/10.1007/978-3-319-53805-1>.
- [7] Zhou H, Yang H, Gong F, Zhou S, Yang Y, Liu H, et al. Case report: *Mycobacterium senegalense* infection after cholecystectomy. Frontiers in Public Health. 2022;10:899846.

PARTICULARS OF CONTRIBUTORS:

1. Postgraduate Tutor, Department of Microbiology, Chettinad Hospital and Research Institute, Chettinad Academy of Research and Education, Chennai, Tamil Nadu, India.
2. Professor and Head, Department of Microbiology, Chettinad Hospital and Research Institute, Chettinad Academy of Research and Education, Chennai, Tamil Nadu, India.
3. Associate Professor, Department of Microbiology, Chettinad Hospital and Research Institute, Chettinad Academy of Research and Education, Chennai, Tamil Nadu, India.
4. Professor, Department of General Medicine, Chettinad Hospital and Research Institute, Chettinad Academy of Research and Education, Chennai, Tamil Nadu, India.

NAME, ADDRESS, E-MAIL ID OF THE CORRESPONDING AUTHOR:

Dr. Priyadarshini Shanmugam,
Professor and Head, Department of Microbiology, Chettinad Hospital and Research Institute, Kelambakkam, Chennai-603103, Tamil Nadu, India.
E-mail: priyadarshini0018@gmail.com

PLAGIARISM CHECKING METHODS: [Jan H et al.]

- Plagiarism X-checker: Dec 13, 2022
- Manual Googling: Jan 12, 2023
- iThenticate Software: Feb 10, 2023 (6%)

ETYMOLOGY: Author Origin

AUTHOR DECLARATION:

- Financial or Other Competing Interests: None
- Was informed consent obtained from the subjects involved in the study? Yes
- For any images presented appropriate consent has been obtained from the subjects. NA

Date of Submission: Dec 08, 2022

Date of Peer Review: Jan 24, 2023

Date of Acceptance: Feb 18, 2023

Date of Publishing: May 01, 2023