

Pseudomonas mendocina Meningitis in a Postoperative Patient: A Case Report and Review of Literature

MITRA KAR¹, AKANKSHA DUBEY², CHINMOY SAHU³, SANGRAM SINGH PATEL⁴

ABSTRACT

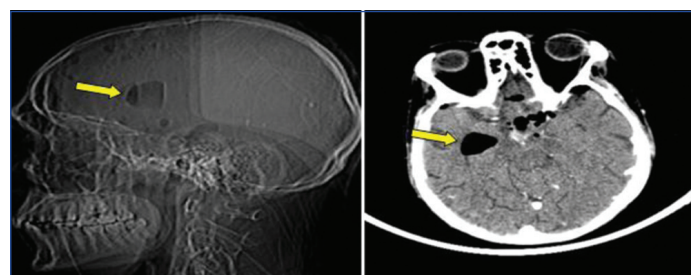
Pseudomonas mendocina is a Gram negative bacillus, belonging to the Pseudomonadaceae family. It was first isolated in 1970 from soil and water of Mendoza region in Argentina. Although, it rarely causes infection, 21 cases of infections ranging from infective endocarditis, bacteraemia, meningitis, soft tissue infections and urinary tract infections are reported worldwide mostly among patients with underlying co-morbidities. This report is the first case of pyogenic meningitis due to *Pseudomonas mendocina* reported from a 1600 bedded teaching hospital in Northern India and second case of *Pseudomonas mendocina* infection from the Indian subcontinent. The presented case was of a 31-year-old female who was diagnosed for pituitary macroadenoma on Magnetic Resonance Imaging (MRI). She underwent endoscopic endonasal trans-sphenoidal excision of the tumour after two months of diagnosing the tumour following which she developed meningitis. On two consecutive aerobic bacterial culture and identification by Matrix-Assisted Laser Desorption/Ionisation-Time of Flight-Mass Spectrometry (MALDI-TOF-MS), growth of *Pseudomonas mendocina* was observed. After Antibiotic Sensitivity Testing (AST) the patient was started on Piperacillin-tazobactam and Amoxicillin-clavulanic acid which lead to alleviate her symptoms of meningitis and was discharged after 27 days of hospital stay.

Keywords: Bacterial meningitis, Cushing's disease, Immunocompromised patients, Opportunistic infections, Pituitary macroadenoma

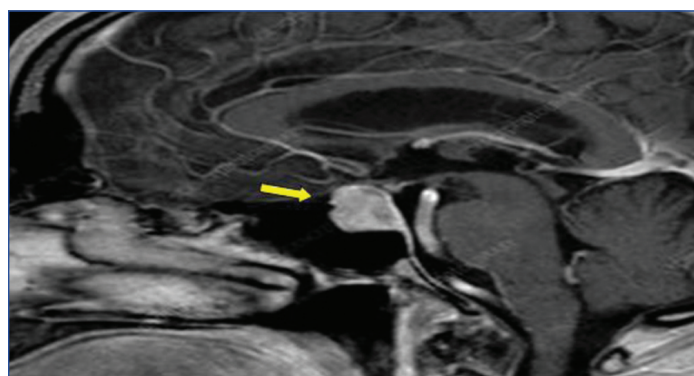
CASE REPORT

A 31-year-old female, presented to the endocrinology Outpatient Department (OPD) with chief complaints of headache and temporal vision loss for the past 20 days and was advised for a MRI brain. Her MRI was suggestive of pituitary macroadenoma, as represented by [Table/Fig-1] and other clinical features like raised blood pressure of 142/98 mmHg, raised blood sugar levels of 346 mg/dL and osteoporotic changes in bones were suggestive of Cushing's disease with no family history of the disease. She was admitted to the endocrinology department for treatment of diabetes insipidus, osteoporosis and was started on cortisol to manage her Cushing's disease and sodium levels were continuously monitored. Due to temporal hemianopsia, she was advised for decompression of the optic nerve and further referred to the Neurosurgery department for evaluating the chances of surgically excising the pituitary tumour. Maintaining aseptic precautions, endoscopic endonasal trans-sphenoidal excision of the tumour was performed after two months of diagnosing the tumour. After the operation, patient was shifted in intubated and unreversed state to the Intensive Care Unit

(ICU). Patient was extubated the next day and the postoperative Computed Tomography (CT) of the head showed a well formed surgical corridor with near total excision of tumour showing evidence of temporal horn pneumocephalus with no evidence of haematoma or infarct, as seen in [Table/Fig-2]. Postoperatively, her requirement for antihypertensive drugs ceased. On her fourth day postsurgery, the patient developed headache and fever for which routine Cerebrospinal Fluid (CSF) examination were performed as shown in [Table/Fig-3], which were suggestive of pyogenic meningitis.



[Table/Fig-2]: Computed Tomography (CT) image of brain showing well formed surgical corridor (yellow arrow) with near total excision of tumour showing evidence of temporal horn pneumocephalus with no evidence of haematoma or infarct postsurgery.



[Table/Fig-1]: T2 weighted Magnetic Resonance Image (MRI) of brain showing Pituitary macroadenoma (shown by yellow coloured arrow in the image) in the patient before surgery.

Routine parameters of CSF for detection of infection	Normal parameters	Parameters of the CSF in case of the patient
Total leukocyte count (per cubic millimeter)	0 to 5	102
CSF glucose (mg/dL)	50 to 80	30
CSF protein (mg/dL)	15 to 40	128
CSF lactate (mmol/ liter)	1-3	9
Microbial examination	No microorganism	Gram negative bacilli seen

[Table/Fig-3]: Routine Cerebrospinal Fluid (CSF) examination suggestive of pyogenic meningitis.

The CSF sample was sent to Bacteriology section of the Department of Microbiology at a tertiary care centre where first a

wet preparation and India ink preparation was performed which showed moderate pus cells, few red blood cells, few motile bacilli and no capsulated microorganisms and simultaneously a Grams stained smear was prepared which showed few pus cells and few Gram negative bacilli, as shown in [Table/Fig-4]. The sample was also inoculated on MacConkey agar and blood agar followed by Robertsons' Cooked Meat (RCM) broth. After 16-18 hours of incubation at 37°C, growth of non lactose fermenting colonies were observed on MacConkey agar, while the growth on blood agar was non haemolytic and pale colonies were observed on nutrient agar, as shown in [Table/Fig-5]. The microorganism was identified as *Pseudomonas mendocina* by MALDI-TOF-MS (Bruker Daltonics, Germany) assay. To confirm that the microorganism was not a mere environmental contaminant, authors requested the clinicians for a repeat sample and it revealed the growth of the same microorganism. A pair of BACTEC blood culture bottles from the patient was also sent on the same day as the repeat CSF sample, but did not flag positive. AST of the isolate using Kirby Bauer disc diffusion method as per the Clinical and Laboratory Standard Institute (CLSI) 2019 guidelines was performed [1]. The isolate was resistant to amikacin, aztreonam, ceftazidime, ciprofloxacin, cefoperazone- sulbactam, imipenem, meropenem and piperacillin- tazobactam and was only found susceptible to colistin with Minimum Inhibitory Concentration (MIC) of 1 µg/ml. As the clinicians did not want to start an antibiotic of last resort in this case they the patient was started on piperacillin-tazobactam 4.5 gram and amoxicillin- clavulanic acid 625 mg TDS and was relieved of fever and headache after 10 days of treatment. The use of a resistant antibiotic could obtain response which can be justified by the 90:60 rule which states that infections due to resistant isolates respond approximately 60% of the time. The 90:60 rule worked in their favour and on discharge she was continued on amoxicillin- clavulanic acid 625 mg TDS, cortisol 100 µg and wyslone (steroid) 5 mg for 14 days. The patient had



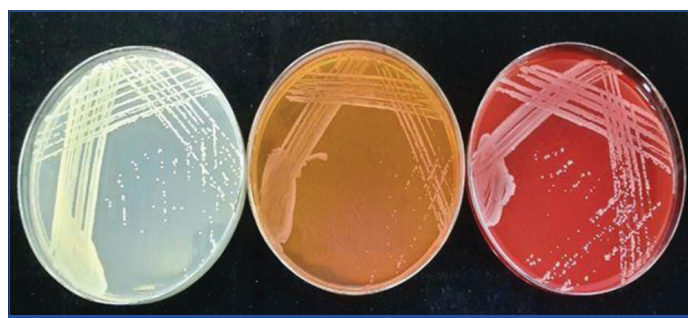[Table/Fig-4]: Grams stained smear showing few pus cells and few Gram negative bacilli (yellow arrow) observed under 100x magnification of a compound microscope.

improved completely at the time of discharge and was advised for follow-up in the neurosurgery OPD after six weeks or in case of altered sensorium, high grade fever and seizure or CSF leak. The patient did not return for follow-up and so her progress could not be recorded any further.

DISCUSSION

Pseudomonas mendocina, belonging to the Pseudomonadaceae family is a gram negative, aerobic and non sporing bacillus. It was originally identified from soil and water of Mendoza region in Argentina in 1970; hence it was named after the region of origin [2]. The microorganism belongs to the *Pseudomonas putida* Group-II and was not recognised to be the cause of infections among humans [3]. The case that deemed this rare organism as a pathogen was infective endocarditis in patient who had undergone aortic valve replacement surgery in Mendoza, Argentina in the year 1992 [4]. Following which, many cases of infection by this rare pathogen in immunocompromised patients have been reported, which include 21 known cases of infections which have been documented from Asia, Europe, Middle-east, North and South America, as demonstrated in [Table/Fig-6] [3-19]. *Pseudomonas mendocina* is a known cause of hospital acquired and opportunistic infections among the immunocompromised patients [20]. Although the microorganism is seldom known to cause infection, its appearance in clinical sample from a patient can account for nosocomial encounter with this pathogen in the duration of prolonged hospital stay.

Seven cases of infections have been reported from South-East Asia by Howe TS et al., Chiu LQ and Wang W, Huang CR et al., and Gupta V et al., of which five cases were immunocompromised while two cases were reported in immunocompetent patients [10,11,15,18]. *Pseudomonas mendocina* wound infection in a diabetic and asthmatic farmer, who was intermittently on steroids, was first recognised by Gupta V et al., in India [18]. Four cases of pyogenic meningitis reported from Taiwan have been known to be caused by this pathogen in 2018 [15].



[Table/Fig-5]: Nutrient agar, MacConkey agar and Blood agar showing colonies of *Pseudomonas mendocina*.

Publication year	Author	Country of publication	Age	Sex	Co-morbidities	Infection
1992	Aragone MR et al., [4]	Argentina	63	Male	Diabetes mellitus type 2, aortic valve replacement, poliomyelitis	Infective endocarditis
2001	Johansen HK et al., [5]	Denmark	28	Female	Situs inversus, double-outlet right ventricle, Ventricular Septal Defect (VSD), pulmonary stenosis, multiple cardiovascular surgeries	Infective endocarditis
2005	Chi CY et al., [6]	Taiwan	65	Male	Alcoholic hepatitis, chronic renal disease	Spondylodiscitis
2007	Mert A et al., [7]	Turkey	36	Male	Mental retardation	Infective endocarditis
2011	Suel P et al., [8]	France	79	Female	Atrial fibrillation, transient ischemic attack, hypertension	Infective endocarditis
2011	Nseir W et al., [9]	Israel	31	Male	Healthy	Bacteraemia
2013	Howe TS et al., [10]	Singapore	86	Female	Vertebral compression fractures, tibial plateau stress fracture	Osteomyelitis
2013	Chiu LQ and Wang W [11]	Singapore	34	Male	Healthy	Septic arthritis
2016	Rapsinski TM et al., [12]	United States	57	Male	Gout, chronic alcohol use	Infective endocarditis

2017	Jerónimo TM et al., [13]	Portugal	22	Male	Chronic kidney disease, peritoneal dialysis	Peritonitis
2018	Almuzara M et al., [14]	Argentina	56	Male	Alcohol use disorder, vascular insufficiency	Burn wound infection
2018	Almuzara M et al., [14]	Argentina	36	Male	Alcohol use disorder	Burn wound infection
2018	Huang CR et al., [15]	Taiwan	55	Male	Diabetes mellitus type 2, buccal cancer, community-acquired infection	Meningitis
2018	Huang CR et al., [15]	Taiwan	66	Female	Spontaneous intracerebral haemorrhage, external ventricular drainage	Meningitis
2018	Huang CR et al., [15]	Taiwan	79	Male	Chronic obstructive pulmonary disease, respiratory failure, nosocomial infection	Meningitis
2018	Huang CR et al., [15]	Taiwan	78	Female	Healthy	Meningitis
2019	Gani M et al., [3]	United States	63	Male	Resistant HIV/AIDS	Bacteraemia
2020	Goldberg ME et al., [16]	United States	72	Male	End-stage renal disease, immunoglobulin A (IgA) nephropathy, atrial fibrillation, heart failure with reduced ejection fraction, obesity, chronic venous stasis	Bacteraemia
2021	Ezeokoli EU et al., [17]	United States	81	Male	Coronary artery disease, atrial fibrillation, heart failure, chronic kidney disease, diabetes mellitus type 2, cerebrovascular accident	Bacteraemia
2021	Gupta V et al., [18]	India	53	Male	Diabetes mellitus type 2, asthma	Leg wound infection
2022	Vo T et al., [19]	United States	83	Male	Diabetes mellitus type 2, hypertension, coronary artery disease, prostate cancer, COVID-19 pneumonia	Urinary tract infection
2023	Present case	India	31	Female	Pituitary macroadenoma with secondary Cushing disease	Meningitis

[Table/Fig-6]: Review of literature on 21 cases of infections caused by *Pseudomonas mendocina* till date (N=22) [3-19].

Authors have recognised the first case of *Pseudomonas mendocina* as a causative agent of pyogenic bacterial meningitis at a Tertiary care centre in Northern India. Earlier cases of bacterial meningitis have been reported from Taiwan in the year 2018 by Huang CR et al., [15]. The preponderance of none of the genders was observed in the studies conducted by them as out of the four patients, 50% were male. All the patients included in the reports by Huang CR et al., were above 50 years of age and had underlying immunocompromised conditions that rendered them easily susceptible to opportunistic infections by rare pathogens, in comparison to index case 31-year-old patient suffering from pituitary macroadenoma [15].

The patient in present case report was admitted for a period of 27 days and during the course of hospital stay after the four days postoperatively she was diagnosed of pyogenic meningitis caused by this rare isolate. Due to her immunocompromised status and underlying co-morbidities including continuous use of cortisol for Cushing's disease, the host was vulnerable to acquire opportunistic infections from the hospital environment as a rare pathogen like *Pseudomonas mendocina* which is an inhabitant of the water and soil [2]. Another cause of infection could be the poor compliance of the hospital staff to infection control measures and hand washing protocol, but the exact source of infection was unidentifiable.

Being a rare pathogen, there was faint knowledge about its antibiotic susceptibility pattern. As *Pseudomonas mendocina* belongs to the *Pseudomonas putida* group (Group-II), which is susceptible to most routine antibiotics, on the contrary, the isolate was rather resistant to most antibiotics [12]. Thus, identification of resistant isolates of *Pseudomonas mendocina* and administration of appropriate antibiotics and their dose adjustment can reduce morbidity among postoperative patients due to meningitis and expedite their recovery. This was the second case of *Pseudomonas mendocina* and the first case of *Pseudomonas mendocina* meningitis reported from India.

CONCLUSION(S)

Pseudomonas mendocina is a rare pathogen known to cause infective endocarditis, bacteraemia, meningitis, and wound ulcers. This is the fifth case of pyogenic meningitis in the world and first case of pyogenic meningitis from India. This case demonstrates the second *Pseudomonas mendocina* related infection in the

Indian subcontinent and identifies her immunocompromised state responsible for acquisition of opportunistic infections caused by uncommon pathogens.

REFERENCES

- [1] Clinical and Laboratory Standards Institute. Performance standards for antimicrobial susceptibility testing: Twenty-third informational supplement. Clinical and Laboratory Standards Institute. CLSI document M100-S29. Wayne, PA, USA (2019).
- [2] Palleroni NJ, Doudoroff M, Stanier RY, Solanes RE, Mandel M. Taxonomy of the aerobic pseudomonads: the properties of the *Pseudomonas stutzeri* group. *Microbiology*. 1970;60(2):215-31.
- [3] Gani M, Rao S, Miller M, Scouler S. *Pseudomonas mendocina* bacteremia: A case study and review of literature. *Am J Case Rep*. 2019;20:453.
- [4] Aragone MR, Maurizi DM, Clara LO, Navarro Estrada JL, Ascione A. *Pseudomonas mendocina*, an environmental bacterium isolated from a patient with human infective endocarditis. *J Clin Microbiol*. 1992;30(6):1583-84.
- [5] Johansen HK, Kjeldsen K, Høiby N. *Pseudomonas mendocina* as a cause of chronic infective endocarditis in a patient with situs inversus. *Clin Microbiol and Infect*. 2001;7(11):650-52.
- [6] Chi CY, Lai CH, Fung CP, Wang JH. *Pseudomonas mendocina* spondylodiscitis: A case report and literature review. *Scand J Infect Dis*. 2005;37(11-12):950-53.
- [7] Mert A, Yılmaz M, Ozaras R, Kocak F, Dagsali S. Native valve endocarditis due to *Pseudomonas mendocina* in a patient with mental retardation and a review of literature. *Scand J Infect Dis*. 2007;39(6-7):615-16.
- [8] Suel P, Martin P, Berthelot G, Robaday S, Etienne M, Chibani A. A case of *Pseudomonas mendocina* endocarditis. *Medecine et Maladies Infectieuses*. 2010;41(2):109-10.
- [9] Nseir W, Taha H, Abid A, Khateeb J. *Pseudomonas mendocina* sepsis in a healthy man. *Isr Med Assoc J*. 2011;13(6):375-76.
- [10] Howe TS, Erlich G, Koh JS, Ng AC, Costerton W. A case of an atypical femoral fracture associated with bacterial biofilm pathogen or bystander? *Osteoporosis International*. 2013;24(5):1765-66.
- [11] Chiu LQ, Wang W. A case of unusual Gram-negative bacilli septic arthritis in an immunocompetent patient. *Singapore Med J*. 2013;54(8):e164-68.
- [12] Rapsinski GJ, Makadia J, Bhanot N, Min Z. *Pseudomonas mendocina* native valve infective endocarditis: A case report. *J Med Case Rep*. 2016;10(1):01-05.
- [13] Jerónimo TM, Malho Guedes A, Stieglmair S, Guerreiro R, Laranjo C, Bernardo I, et al. *Pseudomonas mendocina*: The first case of peritonitis on peritoneal dialysis. *Nefrología (English Edition)*. 2017;37(6):647-49.
- [14] Almuzara M, Montaña S, Carulla M, Sly G, Fernandez J, Hernandez M, et al. Clinical cases of VIM-producing *Pseudomonas mendocina* from two burned patients. *J Glob Antimicrob Resist*. 2018;14:273-74.
- [15] Huang CR, Lien CY, Tsai WC, Lai WA, Hsu CW, Tsai NW, et al. The clinical characteristics of adult bacterial meningitis caused by non *Pseudomonas* (Ps.) *aeruginosa* *Pseudomonas* species: A clinical comparison with Ps. *aeruginosa* meningitis. *Kaohsiung J Med Sci*. 2018;34(1):49-55.
- [16] Goldberg ME, Blyth M, Swiatlo E. *Pseudomonas mendocina* bacteremia in a hemodialysis patient with a central venous catheter. *Cureus*. 2020;12(10):e10853.
- [17] Ezeokoli EU, Polat MU, Ogundipe O, Szela J. A case of *Pseudomonas mendocina* bacteremia in an elderly man with bilateral leg lesions. *Cureus*. 2021;13(9):e17777.
- [18] Gupta V, Singhal L, Pal K, Attri A, Chander J. *Pseudomonas mendocina* wound infection in a farmer: A rare case. *J Clin Diag Res*. 2021;15(2):DD01-DD03.

[19] Vo T, Maisuradze N, Maglakelidze D, Kalra T, McFarlane IM. *Pseudomonas mendocina* urinary tract infection: A case report and literature review. *Cureus*. 2022;14(3):e23583.

[20] Sadikot RT, Blackwell TS, Christman JW, Prince AS. Pathogen-host interactions in *Pseudomonas aeruginosa* pneumonia. *Am J Respir Crit Care Med*. 2005;171(11):1209-23.

PARTICULARS OF CONTRIBUTORS:

1. Senior Resident, Department of Microbiology, Sanjay Gandhi Postgraduate Institute of Medical Sciences, Lucknow, Uttar Pradesh, India.
2. Senior Resident, Department of Microbiology, Sanjay Gandhi Postgraduate Institute of Medical Sciences, Lucknow, Uttar Pradesh, India.
3. Additional Professor, Department of Microbiology, Sanjay Gandhi Postgraduate Institute of Medical Sciences, Lucknow, Uttar Pradesh, India.
4. Associate Professor, Department of Microbiology, Sanjay Gandhi Postgraduate Institute of Medical Sciences, Lucknow, Uttar Pradesh, India.

NAME, ADDRESS, E-MAIL ID OF THE CORRESPONDING AUTHOR:

Dr. Chinmoy Sahu,
Additional Professor, Department of Microbiology, Sanjay Gandhi Institute of
Medical Sciences, Lucknow-226014, Uttar Pradesh, India.
E-mail: csahu78@rediffmail.com

PLAGIARISM CHECKING METHODS: [Jain H et al.]

- Plagiarism X-checker: Nov 29, 2022
- Manual Googling: Jan 10, 2023
- iThenticate Software: Feb 22, 2023 (5%)

ETYMOLOGY: Author Origin

AUTHOR DECLARATION:

- Financial or Other Competing Interests: None
- Was informed consent obtained from the subjects involved in the study? Yes
- For any images presented appropriate consent has been obtained from the subjects. No

Date of Submission: **Nov 28, 2022**

Date of Peer Review: **Dec 23, 2022**

Date of Acceptance: **Feb 27, 2023**

Date of Publishing: **May 01, 2023**