

Hypersensitivity Reaction of Tongue: Oral Adverse Effect of COVID-19 Vaccine: A Case Report

SABARINATH BALARAMAN¹, RAMYA SEKAR², DHANARATHNA SHANMUGAM³, PRABHU SHANKAR DHAYASANKAR⁴



ABSTRACT

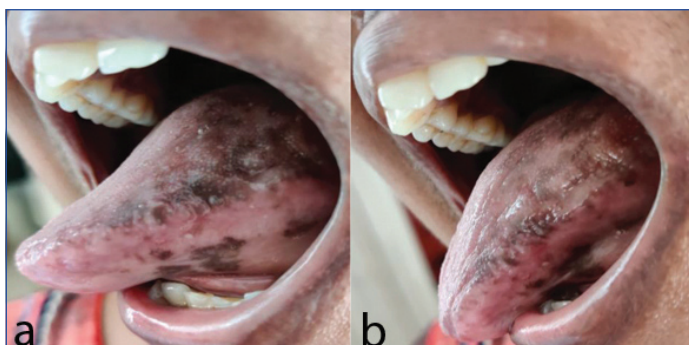Coronavirus Disease-2019 (COVID-19) has introduced the new normal in this 21st century. This viral has caused a great infection storm in the recent past affecting more than half of the world population. Severe Acute Respiratory Syndrome-Coronavirus-2 (SARS-CoV-2) causes various symptoms from mild to severe. Mortality rate has been reported to be low, mostly associated with pre-existing medical history. Literature also states that mortality was high among those with poor immune surveillance. Based on the duration of symptoms, it has been classified into long COVID-19 and short COVID-19 and to combat the outcome of the disease, many vaccines were invented worldwide by various pharmaceutical companies and they helped a lot in controlling the severity of the disease. The vaccines effectively reduced the incidence of long COVID-19 and serious symptoms, thereby, reducing the death rate. Although the vaccines were very effective in control of serious complications of the infection, few patients had certain adverse reactions to the vaccines of both types' whole virus and viral-vector based vaccine. In the present case report, authors would like to document the delayed hypersensitivity reaction in the tongue as a potential Adverse Drug Reaction (ADR) postvaccination for SARS-CoV-2 infection in a 48-year-old female patient without any previous history of medical illness or drug allergy. The ADR was effectively controlled with systemic steroids and the symptoms were effectively controlled within a period of few months.

Keywords: Coronavirus disease-2019, Lichenoid reaction, Medication induced pigmentation, Severe acute respiratory syndrome-coronavirus-2

CASE REPORT

A 48-year-old female patient reported to private clinic in Chennai, complaining of sudden burning sensation of tongue with dull pain for past one week, which was aggravated on taking hot and spicy food. Patient gave a history of first dose of COVID-19 vaccination 10 days prior. Patient had fever of 100° C for one day. Fever subsided after two doses of paracetamol 650 mg. Later, she felt discomfort on taking food followed by severe burning sensation. On self-examination, patient observed abnormal increase in pigmentation on the dorsal, ventral and lateral surface of the tongue, for which, she reported to clinic complaining the same. Patient also reported frequent biting of her tongue for past one week even while taking soft diet. There was no history of diabetes, hypertension or any other drug allergy. Patient had previously undergone preventive vaccination in her childhood and no similar symptoms were reported. No related family history or allergies. Patient gave negative history for deleterious habits.

On intraoral examination, patient had good oral hygiene determined with erythematous oral mucosa and hyperpigmentation all over the tongue. The lateral borders of the tongue had indentations of the teeth indicating inflammation [Table/Fig-1a,b].



[Table/Fig-1a,b]: Patient exhibiting indentations and hyperpigmentation on the dorsal, ventral and lateral surfaces of the tongue.

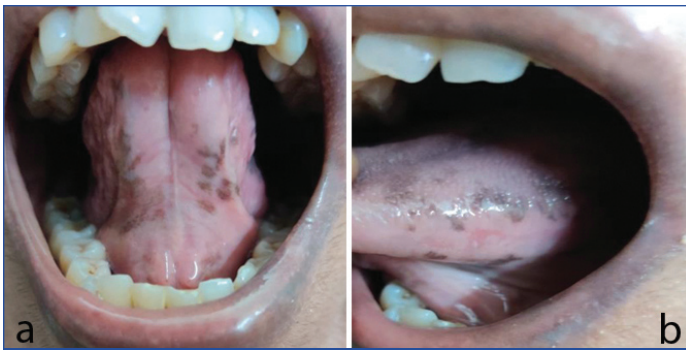Routine blood investigation was done which included complete blood count and diabetic profile. The reports showed mild eosinophilia. On considering the negative history and presence of symptoms in relation to hypersensitivity reaction such as hyperpigmentation, itching, swelling, fever and the investigations showing no abnormalities the above discussed case was diagnosed as hypersensitivity of tongue as an adverse reaction of SARS-CoV-2 vaccination. Viral exanthems and certain bacterial infections can also be present with similar symptoms; due to the absence of other prodromal symptoms these symptoms were ruled out. Steven Johnson syndrome was ruled out due to absence of blistering lesion. As the patient did not accept for biopsy procedure, the authors could not confirm with lichenoid reaction.

Patient was advised for topical steroid gel Triamcinolone (0.1% w/w) (Tess buccal paste, Troikaa Pharmaceuticals Ltd.,) application for three times a day after meals for about five days after which patient was asked to report for follow-up. But after two days of treatment patient reported with increase in pigmentation and tingling sensation along with burning sensation, for which, she was started with systemic steroids, Betamethasone 0.5 mg tablet (Betnesol 0.5 mg. Glaxo SmithKline Pharmaceuticals Ltd.,) twice daily for one week along with the usage of topical steroid which was prescribed already. The lesion started to regress in a weeks' time. The systemic steroids doses were tapered gradually after seven days and stopped. The symptoms were well controlled and by one month, the lesions healed well with reduction in swelling of the tongue [Table/Fig-2a,b].

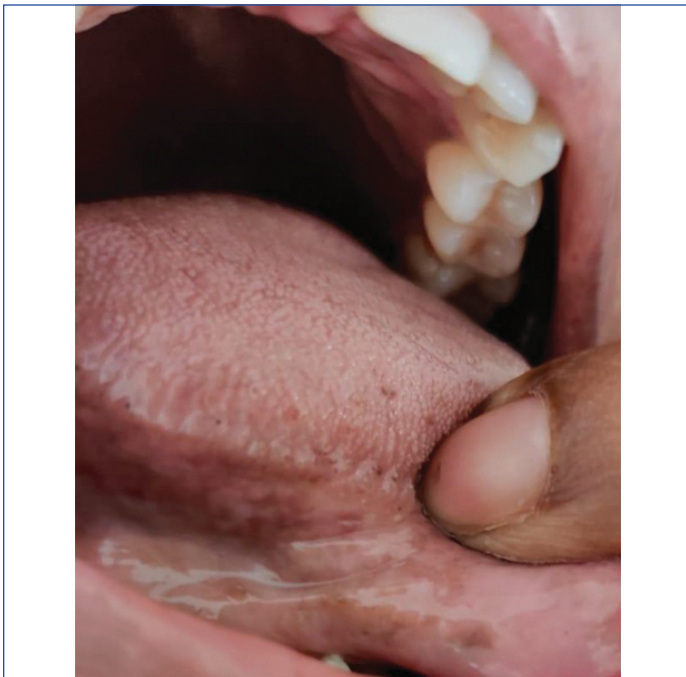
The indentations on the lateral border of the tongue normalised resulting in normal contour, colour and gradual decrease in hyperpigmentation was observed after three weeks. On further follow-up, patient recovered completely [Table/Fig-3].

DISCUSSION

The COVID-19 caused by SARS-CoV-2, has put life under mask and social distancing for about three years now. Number of scientists has tried to untangle the science behind the fast spread and highly



[Table/Fig-2a,b]: Post-treatment with systemic steroids showing reduction in hyperpigmentation and indentations marking lessening of swelling.



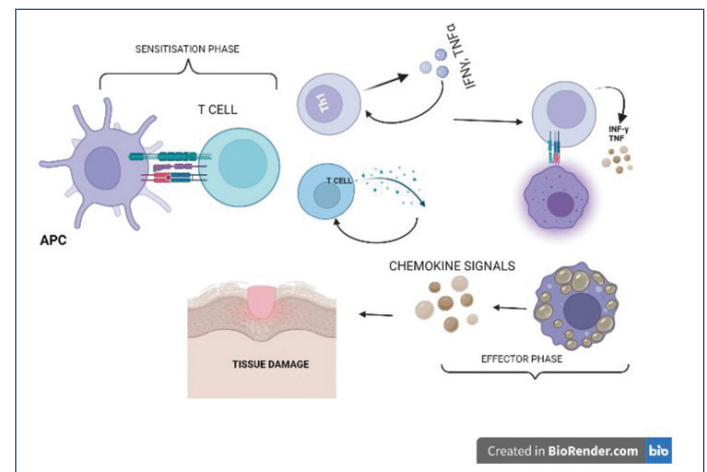
[Table/Fig-3]: Postrecovery picture showing complete resolution of pigmentation and indentation.

mutable potency of this virus. The infection though has a low mortality rate, its efficiency to spread fast and cause life threatening organ damages in many healthy, as well as, immunocompromised individuals was threatening [1]. To lower these serious complications many leading pharmaceutical companies have developed various types of vaccines; many of which have successfully completed clinical trials. India has launched two such vaccines (Whole virus and Viral vector-based vaccine) to render immunity against SARS-CoV-2 [2]. Number of systemic and oral manifestations has been reported post COVID-19 vaccination in India [3]. Delayed Hypersensitivity reactions in the injected arm, marked by symptoms such as erythema, itching, swelling that mimics cellulitis were reported. The onset of these reactions takes minimum 24 to 72 hours and may present for upto 10 days [4].

Delayed hypersensitivity reaction is an immune reaction to various compounds which includes drugs. The manifestation of such reaction is much commonly seen on the skin. These types of reactions commonly occur within hours and some may encounter lesions after days to weeks of exposure. The common signs of delayed type of hypersensitivity include rashes, swelling, itching and fever [5]. These reactions are commonly encountered in the site of injection [6], in the present case report, the authors encountered painful swelling of the tongue, along with burning sensation of the mouth after 24 hours of COVID-19 vaccination. Such delayed reactions are immunologically mediated and are usually self-limiting [7].

Vaccine allergy shares a similar pathogenesis to drug allergy [8]. Vaccines induce protective immune responses, thereby decreases the disease incidence or severity [9]. Allergic reaction to vaccine can

be due to vaccine components such as gelatin, egg protein, and potentially other additives [7]. The inactivated whole virus vaccine Covaxin BBV152, India is a white to off white opalescent suspension free from extraneous particles containing 6 µg of inactivated antigen strain NIV-2020-770, Aluminium hydroxide gel-0.25 mg, TLR7/8 Agonist-15 ug, 2-Phenoxyethanol-2.5 mg and Phosphate-Buffered Saline (PBS)-0.5 mL. Literature shows that 2-Phenoxyethanol, a preservative added in vaccines can cause hypersensitivity reaction [10]. The same has been used in vaccine BBV152 which the patient was injected with. Patient could have developed these reactions due to such components of the vaccine rather than the viral particle. In Japan (2011), influenza vaccine with the same preservative was reported to cause anaphylactic reaction [7]. Similarly, paediatric vaccines with thimerosal as preservative have been avoided due to mercury toxicity [10]. The possible pathophysiology behind this type of hypersensitivity reaction could be activation of Th1 (T helper type 1) cells by the APC which in turn activate the macrophages to produce cytokines like interferon gamma and tumour necrosis factor-alpha. Along with cytokines, reactive oxygen species and reactive nitrogen species are also produced. The synergistic effect of these mediators' cause inflammation and tissue damage [Table/Fig-4] [11,12].



[Table/Fig-4]: Pictorial representation of possible tissue damage and inflammation in delayed hypersensitivity reaction.

APC: Antigen presenting cell; IFN γ : Interferon gamma; TNF α : Tumour necrosis factor alpha (Created by authors with BioRender.com [12])

Evaluation of pigmentation caused due to adverse reaction of vaccine is critical. Many factors such as medical history, drug history, history of hyperpigmentation in any other location, as well the pigmentation intensity has to be considered before the declaration of cause-effect relation. Drugs such as antiretrovirals, Non Steroidal Anti-Inflammatory Drugs (NSAIDs), anticoagulants, antimalarials, antineoplastic drugs, amiodarone and tetracyclines are known to cause mucosal pigmentation [13,14]. Thus, oral mucosal pigmentation as an adverse reaction does not have established pathogenesis and possible causes could be acceleration of α -melanocyte stimulating hormone, increase in melanocyte or increased melanin production. In the present scenario, patient reported that the pigmentation was drastically increased in 24 hours post vaccination.

The ADR to SARS-CoV-2 vaccines such as vesicles, ulcers, plaque, blisters, burning gingiva, bleeding gums and malodour have been reported by Riad A [15]. Mazur M et al., in an observational study, reported burning sensation as the most common oral adverse effect followed by ulceration and swelling [3]. They also found ulcers and swelling in certain cases. Sayare B et al., reported palatal petechiae in response to ChAdOx-nCoV-19 vaccine [16]. Azzi L et al., and Manfredi M et al., also reported oral mucositis as a response to ChAdOx1 and BNT162b2 vaccine [17,18]. Medication induced oral pigmentation has been reported by many authors and a systematic review on the same has been done by Binmadi NO et al., [19].

First choice of treatment for such type of hypersensitivity reaction would be local/systemic corticosteroids, fluid replacement, antibiotics for secondary infections. For oral manifestations, topical steroids are used as first line of treatment. Most of the symptoms are controlled with steroids, severe urticaria has to be treated with anti-histamines along with steroids [12].

CONCLUSION(S)

In the present case report, we have detailed the hypersensitivity reaction on the tongue, as an adverse reaction due to prophylactic vaccination for COVID-19. Although there were no life-threatening complications in this patient, it is evident that an individual could exhibit hypersensitivity reaction towards various components of a vaccine/drug and care should be taken to test for drug sensitivity before administration.

Author's contribution: SB-Conceptualisation, Review; RS-Article writing, Figures preparation; DS-Review; PSD-Review.

REFERENCES

- [1] Chiu NC, Chi H, Tai YL, Peng CC, Tseng CY, Chen CC, et al. Impact of wearing masks, hand hygiene, and social distancing on influenza, enterovirus, and all-cause pneumonia during the coronavirus pandemic: Retrospective national epidemiological surveillance study. *Journal of Medical Internet Research*. 2020;22(8):e21257.
- [2] Krammer F. SARS-CoV-2 vaccines in development. *Nature*. 2020;586(7830):516-27.
- [3] Mazur M, Duś-Ilnicka I, Jedliński M, Ndokaj A, Janiszewska-Olszowska J, Ardan R, et al. Facial and oral manifestations following COVID-19 vaccination: A survey-based study and a first perspective. *International Journal of Environmental Research and Public Health*. 2021;18(9):4965.
- [4] Lindgren AL, Austin AH, Welsh KM. COVID-19-19 arm: Delayed hypersensitivity reactions to SARS-CoV-2 vaccines misdiagnosed as cellulitis. *Journal of Primary Care & Community Health*. 2021;12:21501327211024431.
- [5] Hayes WJ. *Hayes' Handbook of Pesticide Toxicology*. Elsevier/AP; 2010.
- [6] Thomaidou E, Ramot Y. Injection site reactions with the use of biological agents. *Dermatologic Therapy*. 2019;32(2):e12817.
- [7] McNeil MM, DeStefano F. Vaccine-associated hypersensitivity. *Journal of Allergy and Clinical Immunology*. 2018;141(2):463-72.
- [8] Kounis NG, Koniari I, de Gregorio C, Velissaris D, Petalas K, Brinia A, et al. Allergic reactions to current available COVID-19 vaccinations: Pathophysiology, causality, and therapeutic considerations. *Vaccines*. 2021;9(3):221.
- [9] Sadarangani M, Marchant A, Kollmann TR. Immunological mechanisms of vaccine-induced protection against COVID-19 in humans. *Nature Reviews Immunology*. 2021;21(8):475-84.
- [10] Franceschini F, Bottau P, Caimmi S, Crisafulli G, Lucia L, Peroni D, et al. Vaccination in children with allergy to non-active vaccine components. *Clinical and Translational Medicine*. 2015;4(1):01-08.
- [11] Schroder K, Hertzog PJ, Ravasi T, Hume DA. Interferon- γ : An overview of signals, mechanisms and functions. *Journal of Leukocyte Biology*. 2004;75(2):163-89.
- [12] Marwa K, Kondamudi NP. Type IV hypersensitivity reaction. InStatPearls [Internet] 2021 Aug 14. StatPearls Publishing.
- [13] Kounis NG, Frangides C, Papadaki PJ, Zavras GM, Goudevenos J. Dose-dependent appearance and disappearance of amiodarone-induced skin pigmentation. *Clinical Cardiology*. 1996;19(7):592-94.
- [14] Cohen PR. Paclitaxel-associated reticulate hyperpigmentation: Report and review of chemotherapy-induced reticulate hyperpigmentation. *World Journal of Clinical Cases*. 2016;4(12):390.
- [15] Riad A. Oral side effects of COVID-19 vaccine. *British Dental Journal*. 2021;230(2):59.
- [16] Sayare B, Bhardwaj VK, Sharma D. Palatal petechiae: An uncommon oral adverse effect of COVID-19 vaccine. *The Egyptian Journal of Otolaryngology*. 2021;37(1):01-04.
- [17] Azzi L, Toia M, Stevanello N, Maggi F, Forlani G. An episode of oral mucositis after the first administration of the ChAdOx1 COVID-19 vaccine. *Oral Dis*. 2022;28(Suppl 2):2583-85.
- [18] Manfredi M, Ghidini G, Ridolo E, Pizzi S. Oral lesions post injection of the first administration of Pfizer-BioNTech SARS-CoV-2 (BNT162b2) vaccine. *Oral Dis*. 2022;28(Suppl 2):2605-07. Doi: 10.1111/odi.13912.
- [19] Binmadi NO, Bawazir M, Alhindi N, Mawardi H, Mansour G, Alhamed S, et al. Medication-induced oral hyperpigmentation: A systematic review. *Patient Preference and Adherence*. 2020;14:1961.

PARTICULARS OF CONTRIBUTORS:

1. Associate Professor, Department of Oral Pathology, Meenakshi Ammal Dental College, Chennai, Tamil Nadu, India.
2. Assistant Professor, Department of Oral Pathology, Meenakshi Ammal Dental College, Chennai, Tamil Nadu, India.
3. Dentist, Dhanarathna Dental Clinic, Chennai, Tamil Nadu, India.
4. Associate Professor, Department of Oral and Maxillofacial Surgery, Meenakshi Ammal Dental College, Chennai, Tamil Nadu, India.

NAME, ADDRESS, E-MAIL ID OF THE CORRESPONDING AUTHOR:

Ramya Sekar,
Assistant Professor, Department of Oral Pathology and Microbiology,
Meenakshi Ammal Dental College and Hospital, Alapakkam Main Road,
Maduravoyal, Chennai, Tamil Nadu, India.
E-mail: drramyaopath@gmail.com

PLAGIARISM CHECKING METHODS: [Jain H et al.]

- Plagiarism X-checker: Jul 14, 2022
- Manual Googling: Oct 17, 2022
- iThenticate Software: Nov 22, 2022 (2%)

ETYMOLOGY: Author Origin

AUTHOR DECLARATION:

- Financial or Other Competing Interests: None
- Was informed consent obtained from the subjects involved in the study? Yes
- For any images presented appropriate consent has been obtained from the subjects. Yes

Date of Submission: **Jul 12, 2022**

Date of Peer Review: **Sep 12, 2022**

Date of Acceptance: **Nov 24, 2022**

Date of Publishing: **Mar 01, 2023**