

Surgical Approach to Odontogenic Maxillary Sinusitis Caused by Tooth Root Displacement into the Maxillary Sinus: A Case Report

MARCELO DIAS MOREIRA DE ASSIS COSTA¹, ÉTORE GOULART CHAGAS²,
LUDMILA CÁSSIA LOPES PINHEIRO³, LIA DIETRICH⁴, LUIZ RENATO PARANHOS⁵



ABSTRACT

Paranasal sinuses affected by foreign bodies are uncommon clinical situations. Foreign body displacement into facial sinuses is a potential iatrogenic complication, that may cause an oroantral fistula, sinusitis, cellulitis, and subdural emphysema. The maxillary sinus is usually the most affected by tooth displacements, due to its proximity. A dental fragment in the maxillary sinus may cause Odontogenic Maxillary Sinusitis (OMS). The present case report presents a case from the diagnosis to treatment of OMS originated by a fragment of tooth root displacement into the sinus during a previous dental extraction. A female patient, 13-year-old, had characteristic signs of sinusitis, reporting rhinorrhoea, headache, eye pain, and pain on the left side of the face. The clinical examination showed pain on palpation in the buccal region of the upper left first molar, which was absent. The Cone Beam Computed Tomography (CBCT) showed a foreign body inside the maxillary sinus, complete opacification, and bone defect on the sinus floor. Given the final diagnosis of OMS, the treatment selected was the combination of antibiotic therapy and fragment removal from the sinus. The diagnosis, planning, and correct use of surgical techniques described in the literature are essential for preventing iatrogenesis and actively ensuring patient health. In this sense, patients need to be informed about any complication, which should be written in the medical records along with resolution measures.

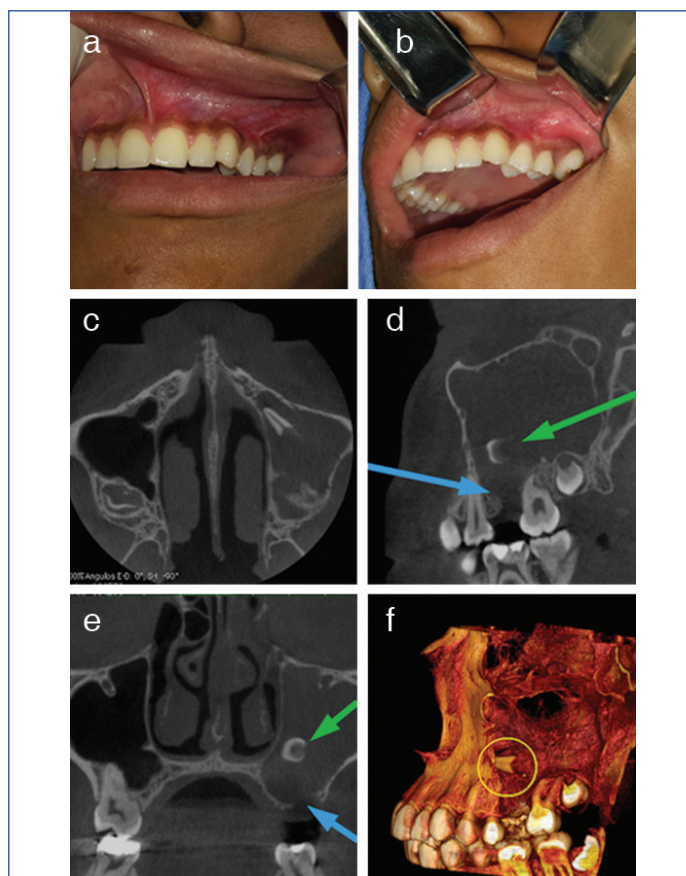
Keywords: Caldwell-Luc technique, Full-thickness flap, Iatrogenic disease, Postoperative complications

CASE REPORT

A female patient, 13-year-old, black, attended the University Hospital, along with her mother for an evaluation of pain on the left side of her face. Nothing stood out in her previous medical history. During the anamnesis and clinical examination, the main complaint was acute pain which worsened when bending over, on the left side of the face, rhinorrhoea, headache, and eye pain, which had been recurrent for three months and increased in the previous week. Such signs and symptoms had never occurred before. The imaging and clinical tests verified extraoral aspects for shape, colour, or size abnormalities, but there were no occurrences. The intraoral analysis showed healthy mucosa with regular colour, the absence of tooth 26, and painful symptoms on palpation in the buccal region of the edentulous area. There was no buccosinusual fistula.

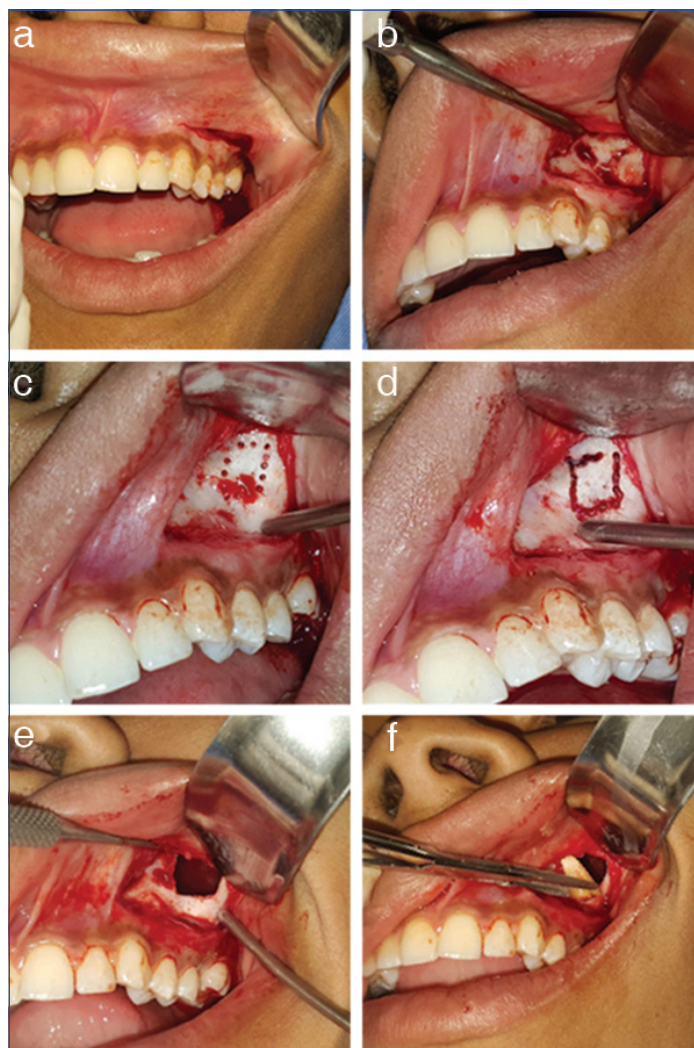
Regarding the onset of symptoms, the patient said, she had been through a dental extraction four months earlier, which presented an intercurrent that she could not explain. The patient provided a low-quality periapical radiograph of the upper left molar region, suggesting the presence of a foreign body inside the maxillary sinus. A CBCT was requested, and the image indicated a root fragment inside the maxillary sinus, complete opacification of the left sinus, and bone defect on the sinus floor, therefore suggesting that the pain and symptoms of the patient referred to OMS [Table/Fig-1].

Before the surgery, amoxicillin was administered along with potassium clavulanate for three days. The upper anterior, middle, and posterior alveolar nerves were blocked using an anaesthetic with a vasoconstrictor. A #15 scalpel blade was used to make a Caldwell-Luc incision on the left side, from the upper canine region to the second molar, followed by a full-thickness flap. Perforations were made in the anterior sinus wall on the zygomaticomaxillary buttress, 5 mm above the roots apexes of the teeth, to delimitate a



[Table/Fig-1]: Preoperative clinical aspect. a) Front view; b) Side view showing the absence of tooth 26. Preoperative tomographic image; c) Axial view; d) Sagittal view; e) Coronal view, with the green arrow indicating root fragment and the blue arrow indicating bone defect on the sinus floor; f) Three-dimensional reconstruction, with the yellow circle identifying the root.

bone window. After removing the bone window, the sinus mucosa was ruptured, showing a purulent secretion. After aspirating the sinus secretion, the root was identified and extracted with a curved haemostat. Next, the sinus cavity was abundantly washed with 0.9% saline solution, and haemostasis and suture were performed. The surgery occurred without intercurrents [Table/Fig-2].



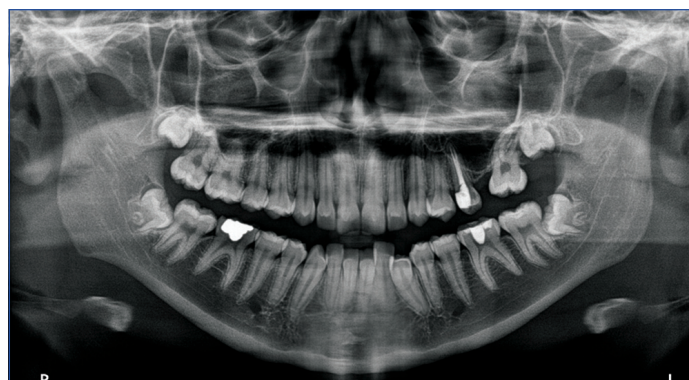
[Table/Fig-2]: (a) and (b) Incision and complete flap detachment; (c) Anterior sinus wall perforations to delimit the bone window; (d) Junction of perforations to produce the bone window; (e) Surgical aspect of the bone window created; (f) Root fragment removal.

The postoperative antibiotic therapy continued for 10 days to manage pain and inflammation, added with 50 mg sodium diclofenac three times a day for three days and 500 mg dipyron four times a day for four days. The patient received postoperative instructions, focusing on not blowing her nose, sneezing with an open mouth and nose, and not using mouth rinses. The patient was observed weekly for one month and showed complete symptom remission and no complications. On the 40th postoperative day, a panoramic radiograph indicated the absence of the maxillary sinus shadow and the root fragment. The patient continued under a monthly follow-up for one year without complications associated with the procedure [Table/Fig-3].

The patient reported a significant improvement in rhinorrhoea, headache, and eye pain immediately after the surgery. There was no more residual pain on the left side of her face after one week. The patient reported that the postoperative period was much easier than after extracting tooth 26.

DISCUSSION

It is a descriptive case report following the Social Chaos And Response Emergency (SCARE) checklist guidelines [1]. Accidents and complications during dental extractions are usual in the daily



[Table/Fig-3]: Postoperative panoramic radiograph with a suggestive image of sinus opacification improvement on the left side and the absence of the root fragment.

routine of dentists [2]. Displaced foreign bodies can appear inside the sinus, including teeth or tooth roots [3]. The maxillary sinus base covers the apices of upper posterior teeth, usually separated from the sinus floor, by either a dense cortical bone with a variable thickness or only by the mucoperiosteum [4]. The literature has reported acute OMS, and the published data show a higher number of cases over the last decades [5]. A recent retrospective analysis found that, approximately 15% of maxillary sinusitis has a dental origin [6].

Maxillary sinusitis is a common condition, usually easily diagnosed. Due to the close anatomic relationship between the maxillary sinus and upper molars, maxillary sinusitis may appear as a toothache. Differing odontogenic orofacial pain from the pain associated with maxillary sinusitis and identifying the origin of sinusitis is relevant for correct treatment intervention. The OMS treatment consists primarily of removing the causal factor [3]. In the present case, the previous history of complications during a posterior maxillary tooth extraction contributed to diagnosing the origin of the sinusitis. The conventional treatment for sinusitis only, with medication would lead to failure because the root permanence would cause recurrences [5].

The CBCT is a reliable resource for planning surgeries inside maxillary sinuses because it produces high resolution [7] three-dimensional images, facilitating the localisation of foreign bodies. It also presents a lower effective radiation dose, lower cost, more access, and lower acquisition time than multislice tomography [8]. The image provided by CBCT facilitates the diagnosis and allows to locate the foreign body, guiding the surgical procedure.

The Caldwell-Luc technique is extensively used to access the maxillary sinus. Despite the recent tendency to endoscopic approaches, the traditional procedure is preferable, when dealing with a large foreign body [9]. The Caldwell-Luc approach is simple, extensively used, dismisses hospitalisation, does not require specific equipment, and a general practitioner can perform it in a standard dental office, hence, its selection.

The European Position Paper on Rhinosinusitis and Nasal Polyps Group ratified complete sinus opacification in computed tomography as an indication for antibiotics for sinusitis [5]. The recommended antibiotic therapy is penicillin of the amoxicillin type associated with potassium clavulanate [10] because *Staphylococcus aureus* is a frequent bacterium in most cases [11]. Amoxicillin associated with potassium clavulanate or clavulanic acid is an accessible and efficient first choice alternative for b-lactamase-producing bacteria in the upper airway. Its use associated with causal factor removal effectively resolved the infection [10].

CONCLUSION(S)

A detailed analysis during the anamnesis and clinical examination provided vital information to the diagnosis and origin of the infection, which is essential for successful sinusitis treatment. The Caldwell-Luc approach in the maxillary sinus is a viable option for dentists

because it is a simple and easy technique, that does not require specific equipment or training.

Ethical approval: The study was submitted to ethical appraisal by the Local Committee (CPEA: 17973319.6.0000.8078), and the person responsible for the patient signed a Consent Form (CF).

REFERENCES

- [1] Agha RA, Borrelli MR, Farwana R, Koshy K, Fowler AJ, Orgill DP, et al. The SCARE 2018 statement: Updating consensus Surgical Case Report (SCARE) guidelines. *Int J Surg.* 2018;60:132-36.
- [2] Gazal G. Management of an emergency tooth extraction in diabetic patients on the dental chair. *Saudi Dent J.* 2020;32(1):01-06.
- [3] Wolf MK, Rostetter C, Stadlinger B, Locher M, Damerou G. Preoperative 3D imaging in maxillary sinus: Brief review of the literature and case report. *Quintessence Int.* 2015;46(7):627-31.
- [4] Arias-Irímia O, Barona-Dorado C, Santos-Marino JA, Martínez-Rodríguez N, Martínez-González JM. Meta-analysis of the etiology of odontogenic maxillary sinusitis. *Med Oral Patol Oral Cir Bucal.* 2010;15(1):e70-73.
- [5] Fokkens WJ, Lund VJ, Hopkins C, Hellings PW, Kern R, Reitsma S, et al. European position paper on rhinosinusitis and nasal polyps 2020. *Rhinology.* 2020;58(Suppl S29):01-464.
- [6] Wuokko-Landén A, Blomgren K, Välimaa H. Acute rhinosinusitis- are we forgetting the possibility of a dental origin? A retrospective study of 385 patients. *Acta Otolaryngol.* 2019;139(9):783-87.
- [7] Kocak N, Alpoz E, Boyacioglu H. Morphological assessment of maxillary sinus septa variations with cone-beam computed tomography in a Turkish population. *Eur J Dent.* 2019;13(1):42-46.
- [8] Yamauchi T, Tani A, Yokoyama S, Ogawa H. Assessment of non-invasive chronic fungal rhinosinusitis by cone beam CT: Comparison with multidetector CT findings. *Fukushima J Med Sci.* 2017;63(2):100-05.
- [9] Şahin MM, Yılmaz M, Karamert R, Cebeci S, Uzunoğlu E, Düzü M, et al. Evaluation of Caldwell-Luc operation in the endoscopic era: Experience from past 7 years. *J Oral Maxillofac Surg.* 2020;78(9):1478-83.
- [10] Saibene AM, Vassena C, Pipolo C, Trimboli M, De Vecchi E, Felisati G, et al. Odontogenic and rhinogenic chronic sinusitis: A modern microbiological comparison. *Int Forum Allergy Rhinol.* 2016;6(1):41-45.
- [11] Aruni AW, Dou Y, Mishra A, Fletcher HM. The biofilm community-rebels with a cause. *Curr Oral Health Rep.* 2015;2(1):48-56.

PARTICULARS OF CONTRIBUTORS:

1. PhD Student, Department of Oral and Maxillofacial Surgery and Dental Implants, Federal University of Uberlândia, Uberlândia, Minas Gerais, Brazil.
2. Undergraduate Student, School of Dentistry, Federal University of Uberlândia, Uberlândia, Minas Gerais, Brazil.
3. Undergraduate Student, School of Dentistry, Faculdade Patos de Minas, Patos de Minas, Minas Gerais, Brazil.
4. PhD, Adjunt Professor, School of Dentistry, Federal University of Vales do Jequitinhonha e Mucuri, Diamantina, Minas Gerais, Brazil.
5. PhD, Associate Professor, Department of Community and Preventive Dentistry, Federal University of Uberlândia, Uberlândia, Minas Gerais, Brazil.

NAME, ADDRESS, E-MAIL ID OF THE CORRESPONDING AUTHOR:

Luiz Renato Paranhos,
School of Dentistry, Federal University of Uberlândia, Uberlândia, Brazil.
Piratini Republic Avenue, s/nº, 4L Block, Umuarama-38400902, Uberlândia,
Minas Gerais, Brazil.
E-mail: paranhos.lrp@gmail.com

PLAGIARISM CHECKING METHODS: [Jan H et al.]

- Plagiarism X-checker: Sep 25, 2022
- Manual Googling: Oct 31, 2022
- iThenticate Software: Nov 15, 2022 (2%)

ETYMOLOGY: Author Origin

AUTHOR DECLARATION:

- Financial or Other Competing Interests: None
- Was informed consent obtained from the subjects involved in the study? Yes
- For any images presented appropriate consent has been obtained from the subjects. Yes

Date of Submission: **Sep 23, 2022**

Date of Peer Review: **Oct 21, 2022**

Date of Acceptance: **Nov 19, 2022**

Date of Publishing: **Mar 01, 2023**