



Preventive Effects of Traditional Plant Concoction “Combo” on the Cyclophosphamide-Induced Ovarian Toxicity in Wistar Rats

Dorcas Okayo Okoroafor^{a*} and Joshua Charles Isirima^b

^a *Department of Biomedical Technology, School of Science Laboratory & Technology, University of Port Harcourt, Port Harcourt, Nigeria.*

^b *Department of Pharmacology, Faculty of Basic Clinical Sciences, College of Health Sciences, University of Port Harcourt, Port Harcourt, Nigeria.*

Authors' contributions

This work was carried out in collaboration between both authors. Both authors read and approved the final manuscript.

Article Information

DOI: 10.9734/AJRIMPS/2023/v12i2213

Open Peer Review History:

This journal follows the Advanced Open Peer Review policy. Identity of the Reviewers, Editor(s) and additional Reviewers, peer review comments, different versions of the manuscript, comments of the editors, etc are available here: <https://www.sdiarticle5.com/review-history/99266>

Original Research Article

Received: 23/02/2023
Accepted: 28/04/2023
Published: 06/05/2023

ABSTRACT

Exposure to chemotherapeutic agents like cyclophosphamide (a drug for cancer treatment), leads to infertility due to its toxic effect on the ovaries. Combo, “a commonly used plant concoction in traditional medicine for the treatment of infertility” is composed of Clove (dried flower), garlic (bulb), ginger (rhizome), and turmeric (rhizome). The aim of this study was to evaluate the possible prophylactic effects of Combo therapy in cyclophosphamide-induced ovarian toxicity in female Wistar rats. Female Wistar rats were divided into 6 groups (A-F) of 6 animals each. Group A (normal control) received distilled water only. Group B (negative control) received 200mg/kg of cyclophosphamide only, while group C (positive control) received only 29mg/kg of Combo. On the

*Corresponding author: E-mail: dorcas.okoroafor@uniport.edu.ng;

other hand, groups D, E and F were pretreated with Combo doses of (15, 29, and 290 mg/kg) and were later treated with 200mg/kg of cyclophosphamide after 7 days. All administrations were done orally. The reproductive hormones assayed were oestrogen and progesterone, while the oxidative stress biomarkers evaluated include glutathione, malondialdehyde, and nitric oxide. Their levels were used as diagnostic markers for assessing the reproductive functions of the ovaries. Combo pre-treatment significantly ($p < 0.05$) decreased the levels of malondialdehyde and nitric oxide, and significantly ($p < 0.05$) increased glutathione, oestrogen and progesterone levels when compared with cyclophosphamide group. Histopathological investigation showed that Combo mitigated degenerative cells in follicles, stromal oedema, and atresia of the follicles when compared with cyclophosphamide group. In conclusion, Combo has fertility potentials and can protect against ovarian degeneration in cyclophosphamide-induced toxicity.

Keywords: Combo; cyclophosphamide; fertility markers; ovarian toxicity; oxidative stress.

1. INTRODUCTION

In recent years the rates of survival of oncological patients have been on the increase due to the greater effectiveness of novel oncological treatment strategies. These treatments however impair reproductive ability due to premature ovarian failure in females [1]. Others reported that the majority of ovarian protectants focused more on the protection against ovarian follicle death, thus, it is important to remember, however, that the stromal environment contributes to follicle health and not just the follicle [2]. Additionally, Sonigo et al. [3] advocated for the conduct of research aimed at limiting follicular loss and protecting the ovaries, including prevention of hormonal deficiencies, which according to them could be used in combination with the currently available fertility preservation techniques.

According to Ndukwu [4] and Nworu [5] phytomedicines are considered safe for their long-term use in a variety of cultures. Nworu advocated for the assessment of herbal products as a priority for herbal research whether for standardization or sourcing of therapeutic compounds of plant origin as well as to create synergy whether in orthodox pharmacotherapy or in traditional plant use. One such synergistic concoction is the combination of Combo, which contains clove (dried flowers), garlic (bulb), ginger (rhizome) and turmeric (rhizome), which are individually useful in the treatment of various ailments due to their various properties, including antioxidant, antiparasitic, antimicrobial, anti-inflammatory, anti-ulcer, and haematological effects [6-10]. After exposure to chemotherapy, which is the major cancer treatment measure in Nigeria [11], chemotherapy-related amenorrhoea (CRA) rates of 30 to 76% [12,13] and 90% Lobo [14] occur. Cyclophosphamide (CYP), an

effective anticancer alkylating agent widely used in cancer treatment also cause toxic effect due to its metabolites, which produce reactive oxygen species. These combine with glutathione to interfere with the Ovary's antioxidant defence system [15]. Reports revealed that treatment with Cyclophosphamide causes an increase in Malondialdehyde (MDA) in the ovary of rats and a reduction in oestrogen and progesterone [16-18]. The toxic effects of Cyclophosphamide on the ovary include reducing the number of primordial, preantral, and antral follicles associated with decreased levels of progesterone and oestrogen hormones [19,20]. Currently, protective agents such as tamoxifen, crocetin and ceramide 1 phosphates used for the mitigation of toxicity of cyclophosphamide on the ovaries all have a limited action on growing follicles, while some have teratogenic effects. Therefore, the need to evaluate the fertility potentials of combo plant therapy on cyclophosphamide-induced ovarian toxicity on Wistar rats will serve as lead to the development of fertility drugs of plant origin.

2. MATERIALS AND METHODS

2.1 Animals

Thirty-six (36) female Wistar rats with average body weight of about 200g were used for the study. They had free access to water and were fed ad libitum with standard feed

2.2 Kits and Test Sample

Estradiol (E_2) and progesterone kits (AccuBind Elisa Microwells, Monobind Inc. Lake Forest, CA92630, USA). Glutathione, malondialdehyde, and nitric oxide assay kits (Elabscience Biotechnology Co., China) were used. Cyclophosphamide tablets were purchased from

Eblend Pharmaceuticals, Unipark. While the clove, garlic, ginger, and turmeric for the preparation of the Combo were purchased from Choba daily market, Port Harcourt, Rivers State, Nigeria.

2.3 Preparation of Combo

Clove, garlic, ginger, and turmeric were washed and chopped. 100g of garlic, ginger, and turmeric each and 50g of clove were soaked in 1000ml of distilled water for 72 hours. This was decanted into a container and labelled "Combo". The dose of Combo, 29mg/kg was based on the dose used locally, 50 ml (2000mg) drinking glass cup for an adult average human (70 kg).

2.4 Phytochemical Screening

The Combo was screened for secondary metabolites. Qualitative phytochemical screening of Combo was done according to the protocol of Odebiyi and Sofowora [21] for the presence of plant secondary metabolites but with slight modification [22] for alkaloids, [23] for saponins, and [24] for phlobatannins, tannins, flavonoids, carbohydrates, anthraquinones, and triterpenes/steroids.

2.5 Experimental Design

Thirty-six Wistar rats were divided into 6 groups (A-F) of 6 animals each. Group A served as normal control and received distilled water only. Group B (negative control) received 200mg/kg of cyclophosphamide only on day 8, while group C (positive control) received only 29mg/kg of Combo for 12 days. On the other hand, groups D, E and F were pre-treated with Combo doses of (15, 29, and 290 mg/kg) and were later treated with 200mg/kg of cyclophosphamide after 7 days that is on day 8 and Combo doses continue till day 14. All administrations were done orally.

2.6 Collection of Serum and Tissue Samples

The animals were euthanized on day 14 under diethyl ether anaesthesia. Serum samples were collected from the jugular vein and used for progesterone and oestrogen, glutathione, malondialdehyde, and nitric oxide assay. For tissue preparation, the ovaries were excised and fixed in 10 % formaldehyde, before the organs were processed and sectioned at 4–5 mm thickness. The tissue sections were collected on

glass slides, and stained with haematoxylin and eosin stains [25,26].

2.7 Determination of Serum Levels of Oestrogen, Progesterone, Glutathione Malondialdehyde, and Nitric Oxide

These assays were performed following the guidelines of the manufacturer's protocol.

2.8 Histopathological Investigation of the Ovaries

The ovaries for the histological studies were coded as follows: Group A; Control (Distilled water only), Group B; received cyclophosphamide only, Group C; received Combo only, Group D; received cyclophosphamide and low dose Combo, Group E; received cyclophosphamide and medium dose Combo, Group F; received cyclophosphamide and high dose Combo.

2.9 Statistical Analysis

A minimum of three replicates were used for each parameter, and the results were expressed as Mean \pm Standard Error of Mean (S.E.M). The data were analysed at $p < 0.05$ statistics using one-way analysis of variance (ANOVA).

3. RESULTS

3.1 Results of Phytochemical Screening

The phytochemical results of the Combo are presented in Table 1 and revealed the presence of alkaloids, saponins, tannins, flavonoids, carbohydrates, and triterpenes/steroids.

Table 1. Preliminary phytochemical

Chemical constituent	Observation
Alkaloids	+
Saponins	+
Phlobatannins	-
Tannins	+
Flavonoids	+
Carbohydrates	+
Free anthraquinones	-
Combine anthraquinones	-
Aglycone (triterpenes)	+
Steroids	+

Note: + = Present; - = Absent

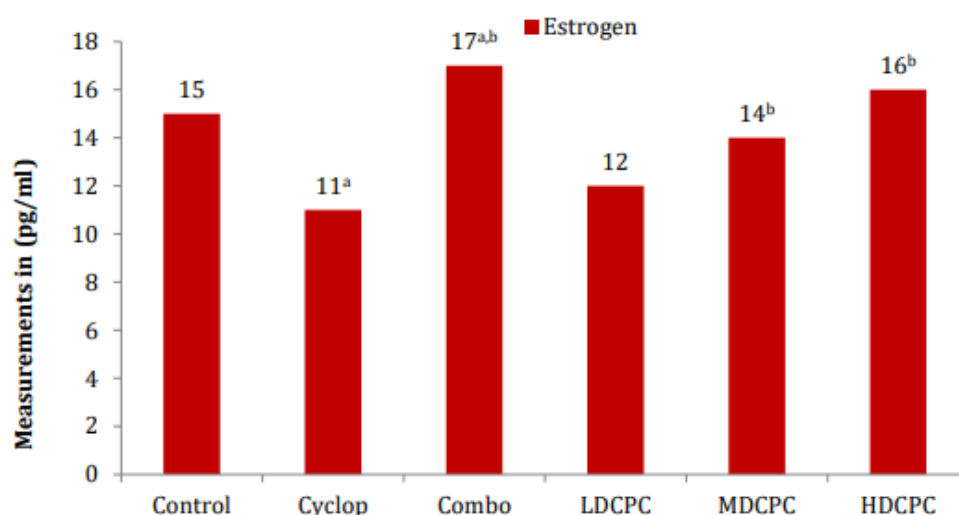


Fig. 1. Effect of cyclophosphamide and combo on Estrogen after 14 days of treatment

3.2 Results of Biochemical Assays

The effect of Combo on oestrogen and progesterone in CYP-treated rats is presented in Fig. 1 and Fig. 2 respectively. The group treated with 200mg/kg of cyclophosphamide showed a significant decrease ($p < 0.05$) in serum oestrogen (11 ± 1.33) and progesterone (17 ± 1.00) when compared to the control group with oestrogen (15 ± 1.53) and progesterone (24 ± 1.15). However, Combo administered at doses 15, 29, and 290 mg/kg in CYP-treated rats significantly ($p < 0.05$) restored the levels of oestrogen and progesterone in serum, as compared to the CYP-treated group.

Administration of Combo alone resulted in a favourable effect on serum antioxidant status as presented in Fig. 3 with GSH level at 74.18 ± 0.10 and control group at 70.34 ± 0.23 , where it significantly reduced MDA level (15.25 ± 0.13) when compared with the control group (19.60 ± 0.31). The group treated with a single dose of 200mg/kg of cyclophosphamide showed that there was an induction of lipid peroxidation as seen in the level of MDA (30.87 ± 0.29) while reducing GSH levels (54.64 ± 0.35). The 7-day pre-treatment of the animals with Combo before the administration of CYP resulted in a significant reduction of lipid peroxidation and compensated the depletion in GSH antioxidants by CYP.

The effect of Combo on the oxidative stress markers MDA, and NO in CYP-treated rats are presented in Fig. 3 and Fig. 4. The levels of MDA (30.87 ± 0.29) and NO (16.12 ± 0.56) significantly increased in CYP-treated rats when compared

with the levels of MDA (19.60 ± 0.31) and NO (13.58 ± 0.03) of the control groups. However, Combo used as pre-treatment at the doses 15, 29, and 290 mg/kg in CYP-treated rats significantly ($p < 0.05$) decreased the elevated MDA in Combo plus CYP group as compared to the CYP group ($p < 0.05$). Combo treatment significantly inhibited the elevation of lipid peroxidation (MDA levels) in serum compared to the CYP-treated group ($p < 0.05$). Moreover, CYP induced lipid peroxidation when compared with the control group. The MDA levels were lower in the Combo group (15.25 ± 0.13) than in the control group (19.60 ± 0.31). The level of MDA decreased at the high dose of Combo (290 mg/kg) compared to the control group, whereas the level of NO at such dose marginally increased compared to the control and combo groups. According to the findings, pre-treatment with Combo reduced the oxidative impact of CYP.

3.3 Histopathology Results

Effects of Combo on ovarian histopathological changes in CYP-treated rats are presented in the photomicrographs of ovarian sections in all the groups are shown in Plate 1 to Plate 12. In the control group, the ovary had normal structure in the cortex and medulla (Plate 1 to Plate 3), containing ovarian cortex with primary follicle (P. follicle) and mature ovarian follicle (M.O. follicle) including corpus luteum, and medullar containing blood vessels. Rats treated with Combo showed similar histology to control group (Plate 6 and Plate 7). Histologically distorted ovary showing ovarian cortex with very few follicles (P. follicles)

were observed in ovarian sections of rats treated with CYP as can be seen in Plate 4 and Plate 5. Ovaries of rats treated daily with Combo for 7 days followed by CYP were able to preserve their

appearance at normal levels as seen in Plate 8 to Plate 12. Histopathological changes were significantly mitigated in Combo plus CYP group as compared with CYP group.

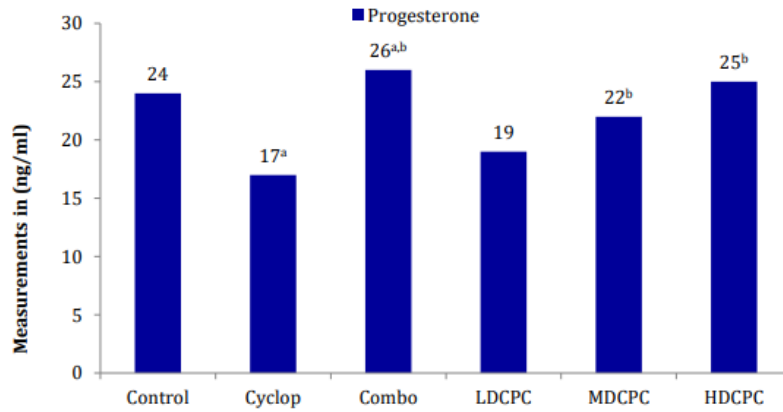


Fig. 2. Effect of cyclophosphamide and combo on progesteron after 14 days of treatment

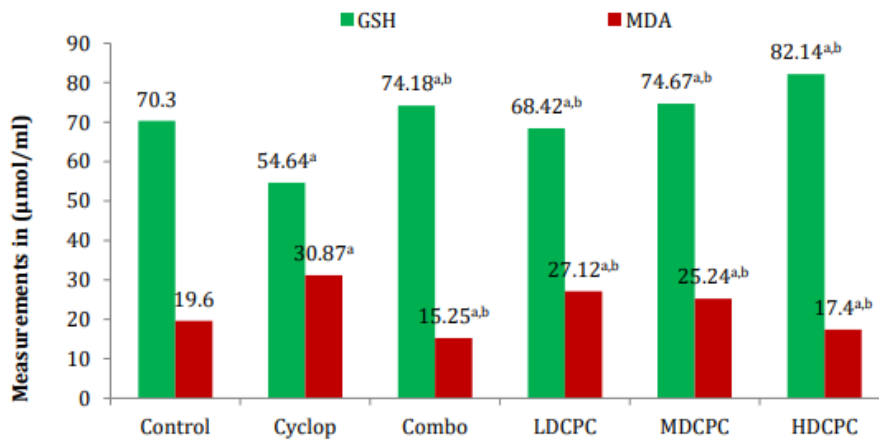


Fig. 3. Effect of cyclophosphamide and combo on some oxidative stress markers after 14 days of treatment

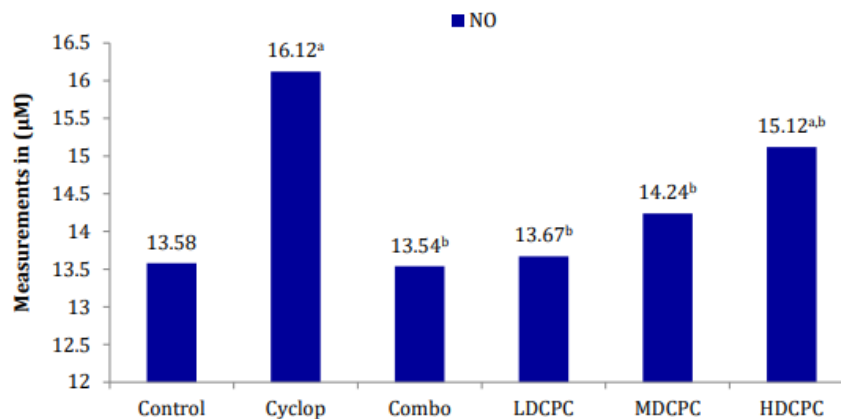


Fig. 4. Effect of cyclophosphamide and combo on nitric oxide after 14 days of treatment

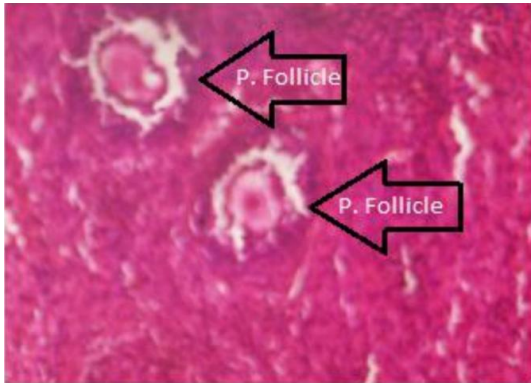


Plate 1. Photomicrograph of Ovary of group A animal, Magnification X 400 H&E stain

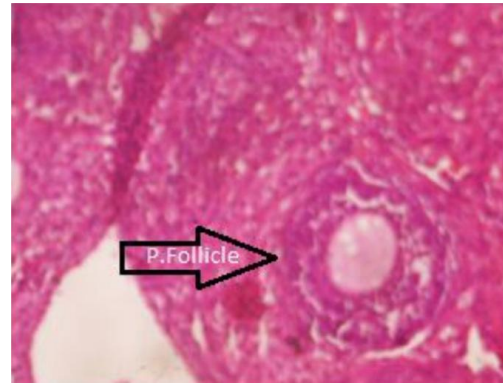


Plate 2. Photomicrograph of Ovary of group A animal, Magnification X 400 H&E stain. Histologically normal ovary showing: ovarian cortex with primary follicle (P. follicle) and medullar containing blood vessels

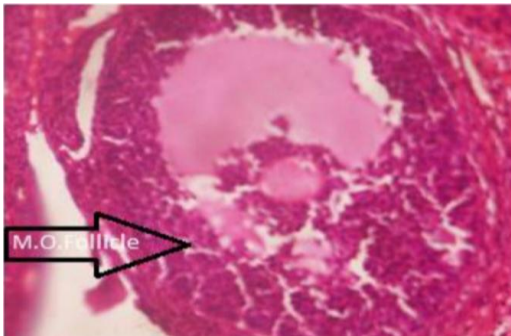


Plate 3. Photomicrograph of Ovary of group A animal, Magnification X 400 H&E stain. Histologically normal ovary showing: ovarian cortex with mature ovarian follicle (M.O. follicle) including corpus luteum, and medullar containing blood vessels

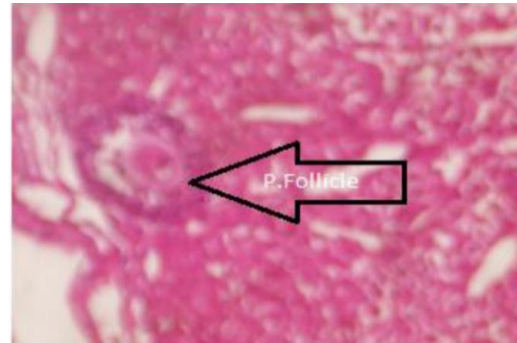


Plate 4. Photomicrograph of Ovary of group B animal, Magnification X 400 H&E stain. Histologically distorted ovary showing ovarian cortex with very few follicles (P. follicles)

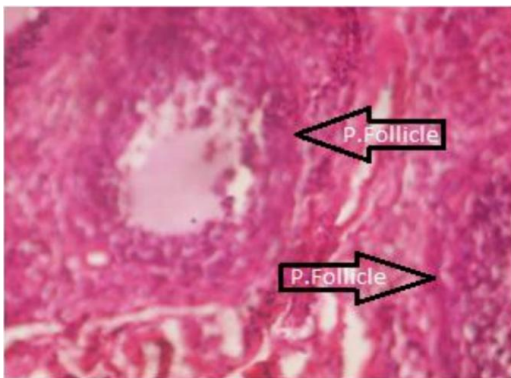


Plate 5. Photomicrograph of Ovary of group B animal, Magnification X 400 H&E stain. Histologically distorted ovary showing ovarian cortex with very few follicles (P. follicles)

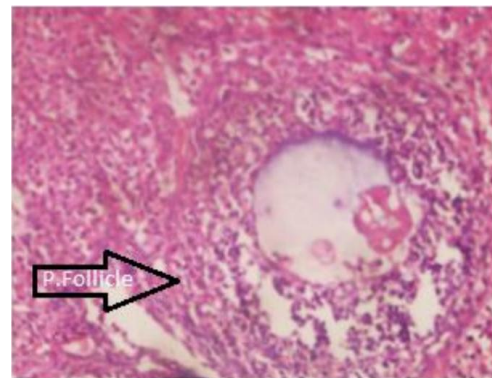


Plate 6. Photomicrograph of Ovary of group C animal, Magnification X 400 H&E stain. Histologically normal ovary showing cortical region with follicle

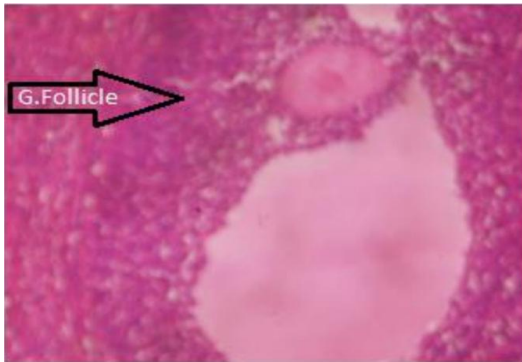


Plate 7. Photomicrograph of Ovary of group C animal, Magnification X 400 H&E stain. Histologically normal ovary showing cortical region with follicles at different stages of development

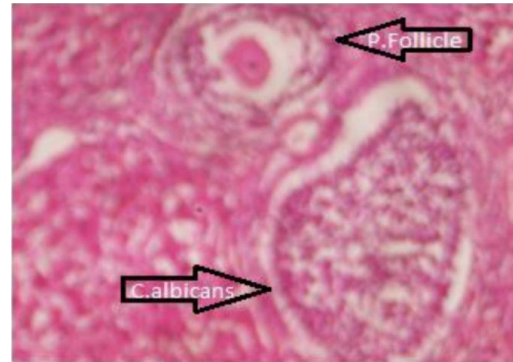


Plate 8. Photomicrograph of Ovary of group D animal, Magnification X 400 H&E stain. Histologically normal ovary showing cortical region with follicles at different stages of development

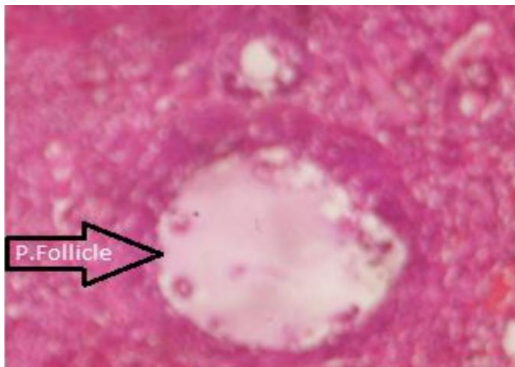


Plate 9. Photomicrograph of Ovary of group D animal, Magnification X 400 H&E stain. Histologically normal ovary

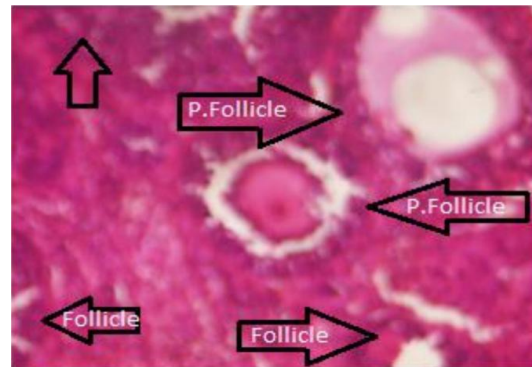


Plate 10. Photomicrograph of Ovary of group E animal, Magnification X 400 H&E stain. Histologically normal ovary showing cortical region with follicles at different stages of development

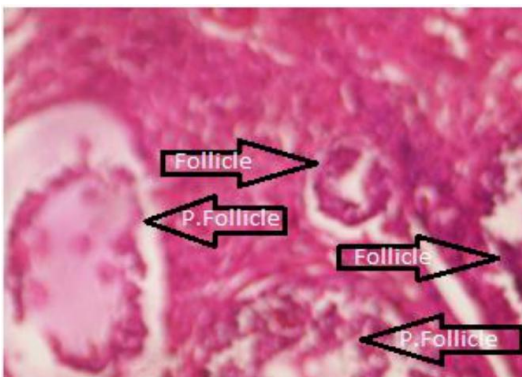

Plate 11. Photomicrograph of Ovary of group F animal, Magnification X 400 H&E stain. Histologically normal ovary. Ovarian cortex containing follicles at different stages of development

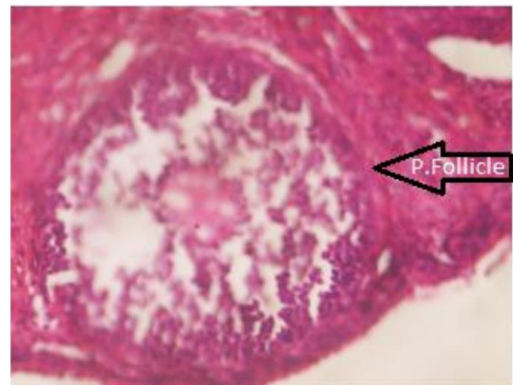


Plate 12. Photomicrograph of Ovary of group F animal, Magnification X 400 H&E stain. Histologically normal ovary

4. DISCUSSION

Significant reduction in oestrogen and progesterone after CYP treatment was observed and is in agreement with Saleh and Mansour's [17] study. But Combo increased the level of these hormones and protected ovarian follicles, ovarian function and structure.

Combo significantly ($p < 0.05$) decreased the levels of malondialdehyde and nitric oxide, while increasing glutathione, oestrogen and progesterone levels when compared with cyclophosphamide groups. Cyclophosphamide caused damage to the ovary resulting in very few follicles in the ovarian cortex. Follicle count would possibly reveal a reduced number of primordial, preantral, and antral follicles as studies have revealed that the toxic effects of Cyclophosphamide on the ovary include reducing the number of primordial, preantral, and antral follicles associated with decreased levels of progesterone and oestrogen [19,20]. Recalling that to maintain fertility and overall health, proper functioning of the ovary is necessary and ovarian function depends on the normal development and maintenance of ovarian follicles. Devine et al. [27] reported evidence of the potential impact of oxidative stress on the well-being of growing primordial cells and pre-ovulatory follicles, including oocytes and early embryos. Phosphoramidate mustard, PM, one of the cytotoxic metabolites of CYP was reported by Devine et al. [27] to be the active metabolite responsible for the anticancer activity with subsequent ovarian toxicity of CYP by elevating the ROS causing oxidative stress, lipid peroxidation and subsequently leading to granulosa cell apoptosis and increased antral follicle atresia. Oxidative and nitrosative damage can occur whenever ROS and RNS react with nucleic acids, cellular lipids, and proteins [28,29]. In the present study, MDA and NO as parameters of oxidative stress and nitrosative damage marker, clearly increased in the serum of CYP-treated rats. These changes have shown that CYP treatment caused oxidative injury to the lipids of the organ.

Combo administration in CYP-treated rats significantly decreased MDA levels and significantly increased the serum antioxidant level of GSH. This can be linked to the reported antioxidant properties [30,31] of the different components of Combo. These results showed that Combo treatment could protect against ovary injury and against the side effects of CYP.

Studies have demonstrated that the high concentrations of the antioxidant GSH in oocytes are necessary for normal fertilization [32], so Combo can be said to possess fertility activities as it increases glutathione levels as shown in Fig. 3.

The phytochemical analysis of Combo revealed that it contains alkaloids, flavonoids, saponins, tannins, and terpenoids. The hormonal and antioxidant activity noticed in Combo can be traced to the presence of these secondary metabolites in the individual components of Combo. Flavonoids are known to be anti-inflammatory, antibiotic, and antioxidants, Saponins are stimulants, hormonal, anti-inflammatory or diuretic, Tannins bind with other molecules helping to detoxify tissues, while Terpenoids are stimulants, hormonal and often anti-inflammatory or diuretic [31].

5. CONCLUSION

In conclusion, Combo has fertility potential and can protect against ovarian degeneration cyclophosphamide-induced toxicity.

6. LIMITATION TO THE STUDY

This study did not present quantitative and qualitative pathological analyses to confirm whether or not there was an improvement in the histology of the ovarian follicles. This study did not take into consideration counts of different types of follicles. Further studies to consider and evaluate these limitations will be carried out in future.

CONSENT

It is not applicable.

ETHICAL APPROVAL

Animal Ethic committee approval has been collected and preserved by the author(s).

COMPETING INTERESTS

Authors have declared that no competing interests exist.

REFERENCES

1. Del-Pozo-Lérida S, Salvador C, Martínez-Soler F, Tortosa A, Perucho M, Giménez-

- Bonafé, P. Preservation of fertility in patients with cancer. *Oncology Reports*. 2019;41(5):2607-2614.
2. Spears N, Lopes F, Stefansdottir A, Rossi V, De Felici M, Anderson RA, Klinger FG. Ovarian damage from chemotherapy and current approaches to its protection. *Human reproduction update*. 2019;25(6): 673–693.
 3. Sonigo C, Beau I, Binart N, Grynberg M. The impact of chemotherapy on the ovaries: Molecular aspects and the prevention of ovarian damage. *International Journal of Molecular Sciences*. 2019;20(21):5342.
 4. Ndukwu BC. Biological diversity: incredible generosity, incredible responsibility. University of Port Harcourt Inaugural Lecture Series No. 96. University of Port Harcourt Press, Nigeria; 2012.
 5. Nworu CS. African herbal pharmacopoeia: Current situation and the need for the standardization of Phytomedicines. Plenary III, 41ST Annual Conference of the West African Society for Pharmacology, Port Harcourt, Nigeria; 2019.
 6. Singh GP, Marimutha HS Murali and Bawa AS. Antioxidative and antibacterial potentials of essential oils and extracts isolated from various spice materials. *Journal of Food Safety*. 2005; 25(2), 130-145.
 7. D'Souza SP, Suvarna V, Chavannavar P, Kanchanaburi B, Niveditha SB. Pharmaceutical perspectives of spices and condiments as alternative antimicrobial remedy. *Journal of Evidence-Based Complementary & Alternative Medicine*. 2017; 22(4) 1002-1010.
 8. Nassan MA, Mohamed EH, Abdelhafez S, Ismail TA. Effect of clove and cinnamon extracts on experimental model of acute hematogenous pyelonephritis in albino rats: Immunopathological and antimicrobial study. *International Journal of Immunopathology and Pharmacology*. 2015; 28(1)60–6
 9. Chand B. Antibacterial effect of garlic (*Allium sativum*) and ginger (*Zingiber officinale*) against *Staphylococcus aureus*, *Salmonella typhi*, *Escherichia coli* and *Bacillus cereus*. *The Journal of Microbiology, Biotechnology and Food Sciences*. 2013;2(4):2481.
 10. Isirima JC and Okoroafor DO. Prevention of doxorubicin-induced haematotoxicity by turmeric in Wistar rats. *World Journal of Advanced Research and Reviews*, 2021; 9(3):096-108.
 11. Okunade KS, Okunola H, Okunowo AA, Anorlu RI. A five-year review of ovarian cancer at a tertiary institution in Lagos, South-West, Nigeria. *The Nigerian Journal of General Practice*. 2016;14(2):23.
 12. Parulekar WR, Day AG, Ottaway JA, Shepherd LE, Trudeau ME, Bramwell V, Pritchard KI. Incidence and prognostic impact of amenorrhea during adjuvant therapy in high-risk premenopausal breast cancer: analysis of a National Cancer Institute of Canada Clinical Trials Group Study—NCIC CTG MA. *Journal of Clinical Oncology*. 2005;23(25):6002-6008.
 13. Abusief ME, Missmer SA, Ginsburg ES, Weeks JC, Partridge AH. The effects of paclitaxel, dose density, and trastuzumab on treatment-related amenorrhea in premenopausal women with breast cancer. *Cancer: Interdisciplinary International Journal of the American Cancer Society*. 2010;116(4):791-798.
 14. Lobo RA. Potential options for preservation of fertility in women. *New England Journal of Medicine*. 2005;353(1):64-73.
 15. Tsai-Turton M, Luong BT, Tan Y, Luderer U. Cyclophosphamide-induced apoptosis in COV434 human granulosa cells involves oxidative stress and glutathione depletion. *Toxicological Sciences*. 2007;98(1):216-230.
 16. Yener NA, Sinanoglu O, Ilter E, Celik A, Sezgin G, Midi A, Aksungar F. Effects of spirulina on cyclophosphamide-induced ovarian toxicity in rats: biochemical and histomorphometric evaluation of the ovary. *Biochemistry Research International*; 2013.
 17. Saleh DO, Mansour DF. Ovario-protective effects of genistein against toxicity in rats: Role of anti-müllerian hormone and oestradiol. *Eur J Pharmacol*. 2016;789:163-171.
 18. Abdel-Aziz AM, Mohamed ASM, Abdelazem O, Okasha AMM, Kamel MY. Cilostazol protects against cyclophosphamide-induced ovarian toxicity in female rats: role of cAMP and HO-1. *Toxicology Mechanisms and Methods*. 2020;1-29.
 19. Yuksel A, Bildik G, Senbabaoglu F, Akin N, Arvas M, Unal F, Oktem O. The magnitude of gonadotoxicity of chemotherapy drugs on ovarian follicles and granulosa cells varies depending upon the category of the drugs and the type of granulosa cells.

- Human Reproduction. 2015; 30(12):2926-2935.
20. Hamzeh M, Hosseinimehr SJ, Mohammadi HR, Beklar SY, Dashti A, Amiri FT. Atorvastatin attenuates the ovarian damage induced by cyclophosphamide in rat: An experimental study. *International Journal of Reproductive BioMedicine*. 2018;16(5):323.
 21. Odebiyi OO, Sofowora EA. Phytochemical Screening of Nigerian Medicinal Plants Part II: Iloydia. 1978;41:1-25.
 22. Harborne JB. *Phytochemical methods: a guide to modern techniques of plant analysis*. 3rd ed. London: Chapman and Hall; 1998.
 23. Sofowora A. *Medicinal Plants and Traditional Medicine in Africa*, 2nd Edn. New York; 1993.
 24. Trease GE, Evans WC. *A textbook of pharmacognosy*. 13th ed. London: Bailliere-Tindall Limited; 1989.
 25. Jones DP. Radical-free biology of oxidative stress. *American Journal of Physiology-Cell Physiology*. 2008;295(4):C849-C868.
 26. Hart JS, Olotu EJ, Paul CW, Yorkum LK, Wogu E. *Anatomical techniques and bioinstrumentation manual*. Ntee Production, Nigeria; 2018.
 27. Devine PJ, Perreault SD, & Luderer U. Roles of reactive oxygen species and antioxidants in ovarian toxicity. *Biology of Reproduction*, 2012; 86(2):27, 1-10.
 28. Roberts RA, Laskin DL, Smith CV, Robertson FM, Allen EM, Doorn JA, Slikker W. Nitrate and oxidative stress in toxicology and disease. *Toxicological Sciences*. 2009;112(1):4-16.
 29. Roede JR, Jones DP. Reactive species and mitochondrial dysfunction: Mechanistic significance of 4-hydroxynonenal. *Environmental and Molecular Mutagenesis*. 2010; 51(5):380-390.
 30. Musavi H, Tabnak M, Sheini FA, Bezvan MH, Amidi F, Abbasi M. Effect of garlic (*Allium sativum*) on male fertility: a systematic review. *Journal of Hermed Pharmacology*. 2018;7(4):306-312.
 31. Deni Bown. *New encyclopaedia of herbs and their uses*. Revised edition. London. Dorling Kindersley Limited; 2008.
 32. Nishihara T, Matsumoto K, Hosoi Y, Morimoto Y. Evaluation of antioxidant status and oxidative stress markers in follicular fluid for human in vitro fertilization outcome. *Reproductive Medicine and Biology*. 2018;17(4):481-486.

© 2023 Okoroafor and Isirima; This is an Open Access article distributed under the terms of the Creative Commons Attribution License (<http://creativecommons.org/licenses/by/4.0>), which permits unrestricted use, distribution, and reproduction in any medium, provided the original work is properly cited.

Peer-review history:

The peer review history for this paper can be accessed here:

<https://www.sdiarticle5.com/review-history/99266>