

# Revaccination after Acute Kidney Injury Associated with Prior COVID-19 Vaccination: Case Report

Senyo Tagboto<sup>1,2,3\*</sup> , Laurette Geldenhuys<sup>2,4,5</sup>

<sup>1</sup>Department of Internal Medicine, Yarmouth Regional Hospital, Yarmouth, Canada

<sup>2</sup>Department of Medicine, Dalhousie University, Halifax, Canada

<sup>3</sup>Department of Internal Medicine, University of Health and Allied Sciences, Ho, Ghana

<sup>4</sup>Department of Pathology, Dalhousie University, Halifax, Canada

<sup>5</sup>Department of Pathology and Laboratory Medicine, Central Zone, Nova Scotia Health, Halifax, Canada

Email: \*senyo2@hotmail.com

**How to cite this paper:** Tagboto, S. and Geldenhuys, L. (2024) Revaccination after Acute Kidney Injury Associated with Prior COVID-19 Vaccination: Case Report. *Advances in Infectious Diseases*, 14, 196-205. <https://doi.org/10.4236/aid.2024.141014>

**Received:** January 8, 2024

**Accepted:** March 12, 2024

**Published:** March 15, 2024

Copyright © 2024 by author(s) and Scientific Research Publishing Inc. This work is licensed under the Creative Commons Attribution-NonCommercial International License (CC BY-NC 4.0). <http://creativecommons.org/licenses/by-nc/4.0/>



Open Access

## Abstract

**Background:** Acute kidney injury associated with proteinuria has been reported following vaccination against SARS-CoV-2 several times since 2021. Decisions about subsequent revaccination in these patients have been difficult because of the uncertainty of the consequences of doing so, and the absence of publications to help determine whether revaccination may be considered safe or not. **Purpose:** We present a case report of a 59-year-old Canadian man who developed severe acute kidney injury associated with moderate proteinuria following his first COVID-19 vaccine with the Moderna vaccine (an mRNA vaccine). He required haemodialysis for 2 weeks, which was initiated when his creatinine reached 1002  $\mu\text{mol/l}$ . A kidney biopsy showed changes consistent with acute tubular necrosis. The patient was cautioned that repeat vaccination might result in further kidney injury which might be irreversible. However, he badly wanted to attempt a second COVID-19 vaccination, to facilitate a family vacation across several countries in Europe, at a time when travel restrictions were in place in many countries for persons who had not completed a course of vaccines. **Method:** Following deliberations, the patient chose to try a different type of Covid-19 vaccine. On this occasion, he was vaccinated with the Novavax vaccine (a subunit COVID-19 vaccine). Following this, close monitoring of his urine to detect proteinuria and blood testing for acute kidney injury were carried out on days 1, 3, 7, and 60 after vaccination. Furthermore, a year after his repeat vaccination, his kidney function and urinalysis were again assessed. **Result and Conclusions:** The patient did not develop acute kidney injury or worsening proteinuria following repeat vaccination. It remains unclear if acute kidney injury with proteinuria is caused by Covid-19 vaccination, or simply an incidental association. This case report suggests that

---

it is may be reasonable for patients with acute kidney injury after COVID-19 vaccination to consider trying a different type of vaccine. In situations where a new virulent strain of virus emerges or in patients at risk of severe complication from infection, it may be reasonable to consider revaccination following appropriate counselling with close monitoring of renal function.

## Keywords

Covid-19, Vaccination, Acute Kidney Injury, Proteinuria, Haemodialysis, Revaccination

---

## 1. Background

Acute kidney injury associated with proteinuria has been reported shortly after vaccination against SARS-CoV-2 several times since 2021. In these patients, it has been difficult to make recommendations about subsequent revaccination during the pandemic.

We report a patient who developed acute kidney injury and proteinuria following his first dose of the Moderna vaccine. He subsequently received the Novavax vaccine with no untoward renal effects. He may have had an incidental viral infection shortly after his initial vaccination.

## 2. Case Report

A 59-year-old Caucasian gentleman started feeling unwell on the 11<sup>th</sup> of May 2021, 4 days after receiving the first dose of the Moderna vaccine (an mRNA vaccine for SARS-CoV-2, composed of nucleoside-modified mRNA encoding a spike protein, encapsulated in lipid nanoparticles). His symptoms included fever, chills, weakness, lethargy, shortness of breath, a decreased appetite, and mild headaches. He also noticed that he was passing little urine and that his urine had become cloudy. He reported at our hospital on the 22<sup>nd</sup> of May because his symptoms continued to worsen.

He had lived in Ontario, Canada for many years and relocated to Nova Scotia in December 2020. He had not had blood tests in the preceding 2 years, but prior to this, his renal function had been normal.

His past medical history included hypertension, gastroesophageal reflux disease, a remote vasectomy, and a fractured arm when he was one year old. At the time of his admission, he was on pantoprazole 40 mg daily and nifedipine 60 mg daily. He was married with three children and was a lifelong non-smoker who drank alcohol socially.

Physical examination at the time of his presentation, demonstrated that he was febrile with a temperature of 38.3°C. He was mildly icteric. His blood pressure was measured at 119/83mmHg and his pulse was 129 beats per minute. His respiratory rate was 22 per minute and his oxygen saturation was 96% on room air. His heart sounds were audible with no murmurs, and his chest was clinically

clear. His abdomen was soft with no organomegaly and otherwise unremarkable, and he had no neurological deficits.

On the day of his admission, his haemoglobin levels were reported at 147 g/l. His white cell count was  $11.9 \times 10^9/l$ , with a mild monocytosis ( $1.7 \times 10^9/l$ ), and low platelet count of  $35 \times 10^9/l$ . His blood film did not demonstrate a microangiopathic picture. His C-reactive protein was elevated at 203 mg/l. His urine contained  $> 3$  g/L of protein on dipstick testing, with 1 - 3 red blood cells per high power field, and 10 - 25 granular casts per low power field. Urine and blood cultures did not grow bacteria. His urine albumin:creatinine ratio was reported as 101.22 mg/mmol. His bilirubin and liver enzymes were elevated (**Table 1**). His renal function was also impaired with his creatinine reaching a peak of 1002  $\mu\text{mol/l}$  on the 26<sup>th</sup> of May, following which he was started on dialysis for a couple of weeks after which his renal function spontaneously recovered (**Table 1**). Antinuclear antibodies, immunoglobulin A, G, and M levels, antineutrophil cytoplasmic antibodies, glomerular basement membrane antibodies and phospholipid A2 receptor antibodies were all negative. Viral screens for Hepatitis A, B and C and for the HIV and Epstein-Barr viruses were negative. Antimitochondrial antibodies and smooth muscle antibodies were negative. Complement levels were not checked. He did not have a demonstrable monoclonal band on serum protein electrophoresis. An abdominal ultrasound reported a mildly echogenic liver and normal sized, non-obstructed kidneys with a mildly hypoechoic renal cortex.

Parvovirus serology was positive for IgM and IgG. SARS-CoV 2 PCR testing was negative as were hepatitis B and C serology. His ferritin levels were elevated on presentation at 5387  $\mu\text{g/l}$  and had returned to normal levels (145  $\mu\text{g/l}$ ) by October 2021.

An abdominal ultrasound showed normal sized, non-obstructed kidneys. These were 10.9 cm long with a mildly hypoechoic cortex. He had a mildly echogenic liver in keeping with hepatic steatosis or mild hepatitis. A non-contrast CT

**Table 1.** Serial laboratory tests following COVID-19 vaccination and re-vaccination.

	22/5/21	26/5/21	12/6/21	16/7/21	19/8/21	25/1/22	28/3/22	27/6/22	4/11/22	27/6/23
Haemoglobin (g/dl)	147	117	92	99	110	122	136	128	140	139
Platelet ( $\times 10^9/l$ )	35	153	276	288	288	281	283	287	227	272
Creatinine ( $\mu\text{mol/l}$ )	700	1002	334	148	141	120	124	128	147	134
CRP (mg/l)	203		30.85	1.31		1.15		1.64		
Bilirubin ( $\mu\text{mol/l}$ )	90	102.8	38.3	8.6		5.5	Second Vaccine dose	7		
ALT (U/L)	198	122	91	21		19		20		
AST (U/L)	217	84	43	16		16		21		
Alkaline Phosphatase (U/L)	151	219	257	75		56		67		
Urine ACR (mg/mmol)	101.22		35.71			<3	<3	<3	<3	<3

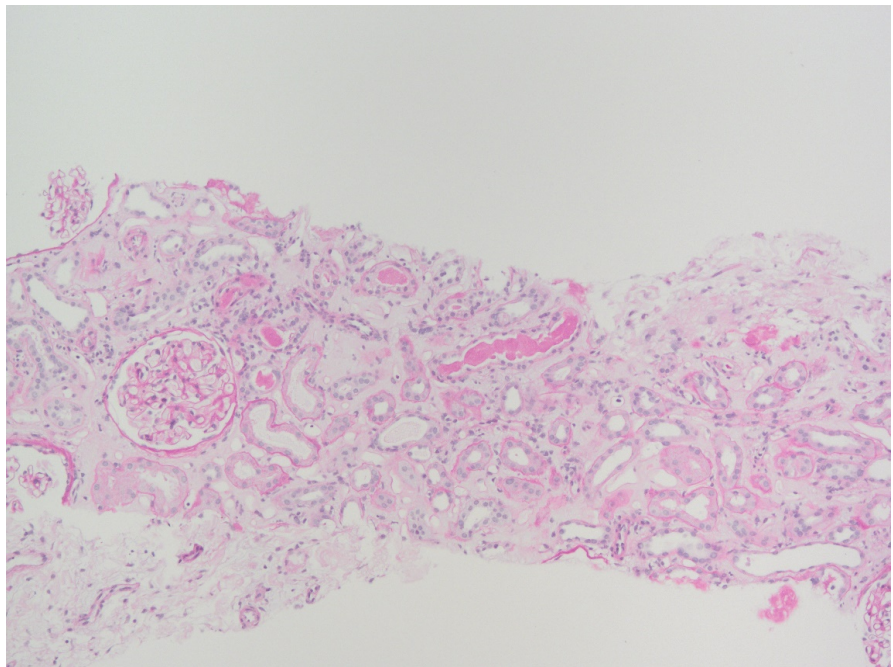
scan of his chest and a chest x-ray showed trivial nonspecific findings including basal opacification. A ventilation perfusion scan did not demonstrate pulmonary emboli. A kidney biopsy was subsequently carried out.

#### KIDNEY BIOPSY

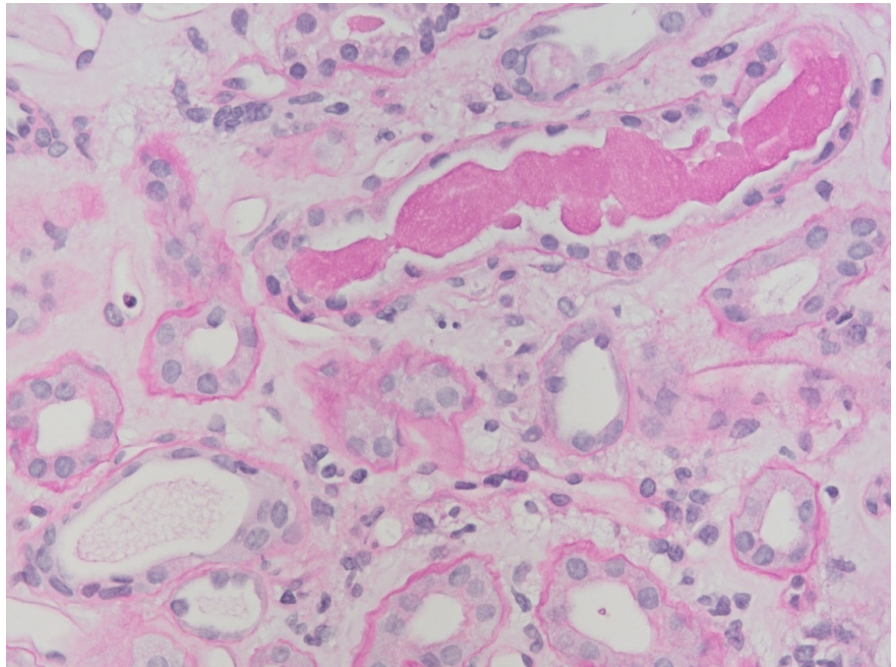
Light microscopy showed unremarkable glomeruli, apart from one that was globally sclerosed. Several tubules were dilated with and demonstrated flattened epithelium, and several contained granular casts, consistent with acute tubular necrosis (**Figure 1** and **Figure 2**). There was a mild interstitial lymphoid infiltrate in a background of mild chronic tubulointerstitial and vascular change. Immunofluorescence was negative and electron microscopy showed mild non-specific changes, including a single podocyte containing zebra bodies (**Figure 3**).

His pantoprazole was stopped on the basis that this drug has been associated with interstitial nephritis but given the time course relationship to the COVID-19 vaccination, he was advised to avoid further COVID-19 vaccinations and given a medical certificate to this end.

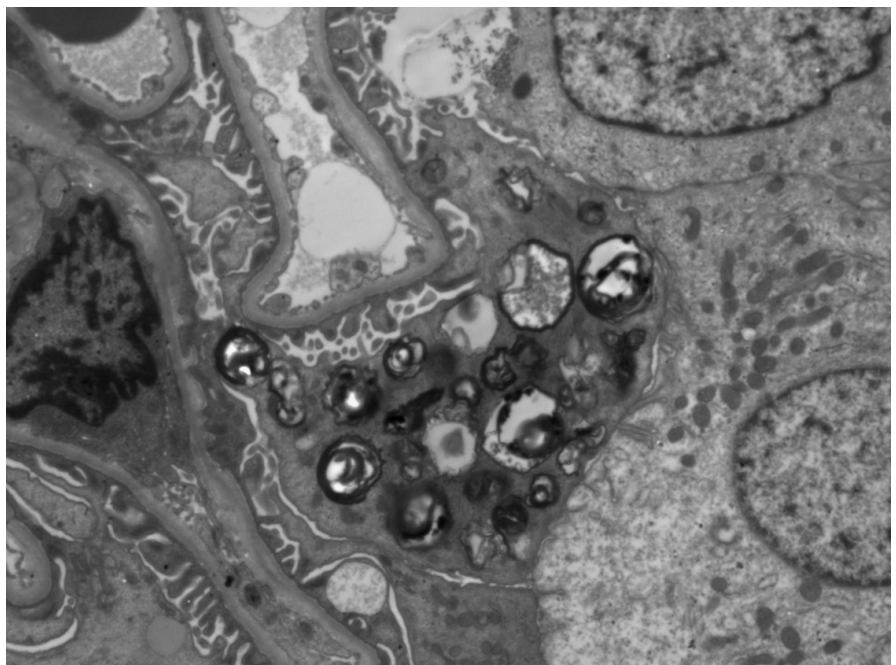
He had however planned to travel to several countries in Europe and was concerned that not being vaccinated might leave him open to illness abroad. Furthermore, at the time there were travel restrictions to travel without full vaccination in some countries, as such, he chose to be vaccinated with a different type of COVID-19 vaccine. He subsequently received further vaccination with the Novovax vaccine on the 25<sup>th</sup> of April 2022. On this occasion, his kidney function remained normal, and he did not develop proteinuria on days 1, 3, 7 or 60 after vaccination (**Table 1**). Follow-up a year after his second dose of COVID-19



**Figure 1.** Dilated tubules with flattened epithelium and granular casts, consistent with acute tubular necrosis. PAS stain 100×.



**Figure 2.** Dilated tubules with flattened epithelium and granular casts, consistent with acute tubular necrosis. PAS stain 400×.



**Figure 3.** Electron micrograph showing zebra bodies in a single podocyte. 4000×.

vaccination demonstrated stable kidney function and the absence of proteinuria (Table 1).

### 3. Discussion

Acute kidney injury associated with proteinuria has been reported shortly after

vaccination against SARS-CoV-2 several times since 2021. This has been reported following the BNT162b2 vaccine (Pfizer-BioNTech). In one case report the serum creatinine level on admission was 2.31 mg/dL (204.25  $\mu\text{mol/l}$ ) and the 24-hour urinary protein excretion was 6.9 grams [1]. In another case report, a week after vaccination the 24-hour urine protein loss was reported as 23.2 g/d, and serum creatinine levels were 2.33 mg/dl (206.02  $\mu\text{mol/l}$ ) [2]. A third instance occurred 10 days after the first dose of the Pfizer-BioNTech COVID-19 vaccine in a male patient with an elevated urine albumin to creatinine ratio of 668 mg/mmol, associated with mildly elevated serum creatinine levels of 116  $\mu\text{mol/L}$  from a baseline of 79  $\mu\text{mol/L}$  [3]. The renal biopsies in these cases were consistent with minimal change disease.

The same clinical presentation has also been described following the Moderna mRNA-1273 vaccine. In one report, this occurred less than a week after the first dose of the vaccine, with 24-hour urine protein loss measured at 13.4 g. In this instance, a renal biopsy showed mild acute tubular injury with severe foot process effacement in all identified podocytes. Focal areas of interstitial nephritis were also present with tubulointerstitial fibrosis in about 10% of the biopsy sample. Four of the 69 sampled glomeruli were globally sclerosed. Serum creatinine levels were elevated at 1.48 mg/dl (130.86  $\mu\text{mol/l}$ ) compared to baseline levels of 0.7 mg/dl (61.89  $\mu\text{mol/l}$ ) [4]. In another report, a 43-year-old man developed sudden-onset bilateral pedal oedema 7 days after the Moderna vaccine. Serum creatinine levels at presentation were 80  $\mu\text{mol/l}$ . He had 15 g of proteinuria which decreased to 1 g, two weeks after initiating steroid therapy with prednisolone. Two weeks later, his serum creatinine levels were 61  $\mu\text{mol/l}$  and a renal biopsy showed concomitant minimal change disease and IgA nephropathy [5].

Acute kidney injury has also been reported following the Oxford-AstraZeneca Covid-19 vaccine in a 71-year-old man with baseline creatinine levels of 0.7 mg/dL (61.89  $\mu\text{mol/l}$ ) who developed a urinary protein to creatinine ratio of 2321 mg/mmol, oliguria, refractory hyperkalemia and fluid overload prompting the initiation of haemodialysis [6].

A systematic review of renal disease following COVID-19 vaccination was published in October 2021, and included 48 cases from 36 articles. Minimal change disease (19 cases) was the most frequent pathology observed, followed by IgA nephropathy (14 cases) and vasculitis (10 cases). Other cases included acute rejection of a kidney transplant, a relapse of membranous nephropathy, new-onset renal thrombotic microangiopathy, a relapse of IgG4 nephritis, and scleroderma renal crisis following COVID-19 vaccination. In all these instances, renal recovery was typical without the need for long-term renal replacement therapy [7].

Viral infections are well known causes of kidney pathology. The pathogenesis includes tropism of the virus in the kidney, direct cytopathogenic effects, induction of abnormal immune complexes, and multiorgan failure. Hepatitis B virus is known to be associated with membranous nephropathy and mesangiocapillary glomerulonephritis. Hepatitis C virus has been associated with several types of

glomerulonephritis, including cryoglobulinemic glomerulonephritis. The yellow fever virus, hepatitis A virus, the measles virus and Epstein-Barr virus are thought to be associated with glomerulonephritis, and other viruses, such as mumps, measles, varicella and herpes have a rare or speculative role in glomerulonephritis. HIV may cause collapsing focal segmental glomerulosclerosis and other forms of immune complex glomerulonephritis. Hantaviruses and coronaviruses associated with the acute respiratory syndrome can lead to acute renal failure. BK virus, Dengue fever, Epstein-Barr virus, influenza A, Coxsackie B virus and cytomegalovirus have been associated with interstitial nephritis. Recent reports may indicate a role for parvovirus B19 in idiopathic collapsing focal segmental glomerulosclerosis [8], and acute hepatitis has been described following parvovirus infections [9]. A study in a French Hospital examined the sera of 100 consecutive patients who had undergone kidney biopsies in 2017-2018 for parvovirus infection with IgG, IgM and viral DNA. Sixty-seven patients had IgG antibodies and 8 of these also had IgM antibodies without viral DNA. Four cases were deemed to have clear evidence of parvovirus B19 infection and the pathology reports included lupus like glomerulonephritis, minimal change with tubular necrosis, secondary haemolytic uraemic syndrome and membranoproliferative glomerulonephritis respectively. The authors conclude that it remains unclear if parvovirus B19 is nephrotoxic or triggers renal endothelial cell injury or immune activation [10].

In a single case report of a patient who died after COVID-19 infection and who had received hydroxychloroquine for 5 days, zebra-like bodies were noted in the kidney biopsies, a finding typically seen in Fabry disease [11]. Zebra bodies are intra-lysosomal osmiophilic lamellar inclusions that are generally found in podocytes but can also be found elsewhere including mesangial and tubular cells. These inclusion bodies are classically associated with Fabry disease, an X-linked inherited condition causing alpha-galactosidase A deficiency, leading to an intracellular accumulation of globotriaosylceramide and related glycosphingolipids in the kidney and many other cells in the body [11]. Hydroxychloroquine and related drugs like chloroquine and amiodarone [12] have structural properties of hydrophilic and hydrophobic regions that facilitate their passage through lysosomal membranes and accumulation within the organelles, giving a histological appearance similar to Fabry disease, typically with long-term use. In this report, it was felt unlikely that the brief use of hydroxychloroquine was responsible for the histological picture. Phospholipidosis induced by drugs is dose-dependent and is reversible after stopping the causative medication [13]. It has been suggested that renal injury due to COVID-19 may be due to immune complex formation. It has been debated whether the zebra bodies in this single case report is a form of immune injury. Hydroxychloroquine-related kidney disease is known to be rare. In parts of the world where hydroxychloroquine is commonly used to treat malaria infections, there are no case reports of zebra-like bodies in postmortem examinations on individuals with severe malaria and renal failure who received therapy with hydroxychloroquine [14]. Apart

from a single report of zebra bodies seen in kidney disease associated with SARS-CoV-2 [11], this lesion has not been described in any case of renal disease following the COVID-19 vaccination to date.

Antibodies against the spike protein S1 of SARS-CoV-2 has a high affinity for human tissue proteins transglutaminase 3, transglutaminase 2, anti-extractable nuclear antigen, nuclear antigen, and myelin basic protein which is the same viral protein that the mRNA vaccine codes for. There have been reports of immune thrombocytopaenia and immune hepatitis following COVID-19 vaccination with some speculation that vaccination may unmask autoimmune disease in predisposed persons [15]. However, it still remains unclear whether COVID-19 vaccination directly causes renal injury or whether the reports of renal injury following vaccination are incidental. Additionally, it remains unclear whether revaccination with different forms of COVID-19 vaccination is safe.

#### **4. Conclusion**

We report a case of successful revaccination, after an episode of acute kidney injury and proteinuria following an initial COVID-19 vaccination, albeit with a different type of vaccine. This may suggest that different vaccines may not necessarily induce the same immunopathology, or that some reports of acute kidney injury and proteinuria associated with vaccination may be incidental. Although it is difficult to make generalizations, in selected patients at risk of severe COVID-19 infections, or in situations where a new virulent strain of virus emerges, it may be reasonable to consider revaccination following appropriate counselling with close monitoring of renal function immediately after vaccination, and perhaps considering an early trial of steroid therapy if kidney injury recurs. The patient was delighted that revaccination was uneventful and that this permitted him travel across Europe with his family at a time when travel restrictions for incompletely vaccinated individuals were in place.

#### **Written Consent**

Written consent was obtained from the patient for this publication.

#### **Data Availability**

All data and material regarding this publication is available in electronic form.

#### **Authors' contributions**

Senyo Tagboto conceptualized this research. Both authors wrote and edited the manuscript.

#### **Conflicts of Interest**

The authors declare no conflicts of interest regarding the publication of this paper.



## References

- [1] Lebedev, L., Sapojnikov, M., Wechsler, A., Varadi-Levi, R., Zamir, D., Tobar, A., Levin-Iaina, N., Fytlovich, S. and Yagil, Y. (2021) Minimal Change Disease Following the Pfizer-BioNTech COVID-19 Vaccine. *American Journal of Kidney Diseases*, **78**, 142-145. <https://doi.org/10.1053/j.ajkd.2021.03.010>
- [2] D'Agati, V.D., Kudose, S., Bombardieri, A.S., Adamidis, A. and Tartini, A. (2021) Minimal Change Disease and Acute Kidney Injury Following the Pfizer-BioNTech COVID-19 Vaccine. *Kidney International*, **100**, 461-463. <https://doi.org/10.1016/j.kint.2021.04.035>
- [3] Hanna, J., Ingram, A. and Shao, T. (2021) Minimal Change Disease After First Dose of Pfizer-BioNTech COVID-19 Vaccine: A Case Report and Review of Minimal Change Disease Related to COVID-19 Vaccine. *Canadian Journal of Kidney Health and Disease*, **8**. <https://doi.org/10.1177/20543581211058271>
- [4] Holzworth, A., Couchot, P., Cruz-Knight, W. and Brucculeri, M. (2021) Minimal Change Disease Following the Moderna mRNA-1273 SARS-CoV-2 Vaccine. *Kidney International*, **100**, 463-464. <https://doi.org/10.1016/j.kint.2021.05.007>
- [5] Thappy, S., Thalappil, S.R., Abbarh, S., Al-Mashdali, A., Akhtar, M. and Alkadi, M.M. (2021) Minimal Change Disease Following the Moderna COVID-19 Vaccine: First Case Report. *BMC Nephrology*, **22**, Article No. 376. <https://doi.org/10.1186/s12882-021-02583-9>
- [6] Leclerc, S., Royal, V., Lamarche, C. and Laurin, L.P. (2021) Minimal Change Disease With Severe Acute Kidney Injury Following the Oxford-AstraZeneca COVID-19 Vaccine: A Case Report. *American Journal of Kidney Diseases*, **78**, 607-610. <https://doi.org/10.1053/j.ajkd.2021.06.008>
- [7] Wu, H.H.L., Kalra, P.A. and Chinnadurai, R. (2021) New-Onset and Relapsed Kidney Histopathology Following COVID-19 Vaccination: A Systematic Review. *Vaccines*, **9**, Article No. 1252. <https://doi.org/10.3390/vaccines9111252>
- [8] Lai, A.S. and Lai, K.N. (2006) Viral Nephropathy. *Nature Clinical Practice Nephrology*, **2**, 254-262. <https://doi.org/10.1038/ncpneph0166>
- [9] Leon, L.A.A., Alves, A.D.R., Garcia, R.C.N.C., Melgaço, J.G., de Paula, V.S. and Pinto, M.A. (2017) Parvovirus B19 Infection in a Fatal Case of Acute Liver Failure. *The Pediatric Infectious Disease Journal*, **36**, e355-e358. <https://doi.org/10.1097/INF.0000000000001731>
- [10] Kauffmann, M., Bobot, M., Daniel, L., Torrents, J., Knefati, Y., Moranne, O., Burtey, S., Zandotti, C. and Jourde-Chiche, N. (2020) Parvovirus B19 Infection and Kidney Injury: Report of 4 Cases and Analysis of Immunization and Viremia in an Adult Cohort of 100 Patients Undergoing a Kidney Biopsy. *BMC Nephrology*, **21**, Article No. 260. <https://doi.org/10.1186/s12882-020-01911-9>
- [11] Obeidat, M., Isaacson, A.L., Chen, S.J., Ivanovic, M. and Holanda, D. (2020) Zebra-Like Bodies in COVID-19: Is Phospholipidosis Evidence of Hydroxychloroquine Induced Acute Kidney Injury? *Ultrastructural Pathology*, **44**, 519-523. <https://doi.org/10.1080/01913123.2020.1850966>
- [12] Pintavorn, P. and Cook, W.J. (2008) Progressive Renal Insufficiency Associated with Amiodarone-Induced Phospholipidosis. *Kidney International*, **74**, 1354-1357. <https://doi.org/10.1038/ki.2008.229>
- [13] Reasor, M.J. and Kacew, S. (2001) Drug-Induced Phospholipidosis: Are There Functional Consequences? *Experimental Biology and Medicine*, **226**, 825-830. <https://doi.org/10.1177/153537020122600903>

- [14] Mungmunpantipantip, R. and Wiwanitkit, V. (2021) Zebra-Like Bodies in COVID-19, Hydroxychloroquine, and Acute Renal Injury. *Ultrastructural Pathology*, **45**, Article No. 78. <https://doi.org/10.1080/01913123.2020.1866130>
- [15] Bril, F., Al Diffalha, S., Dean, M. and Fettig, D.M. (2021) Autoimmune Hepatitis Developing after Coronavirus Disease 2019 (COVID-19) Vaccine: Causality or Casualty? *Journal of Hepatology*, **75**, 222-224. <https://doi.org/10.1016/j.jhep.2021.04.003>