



PREVALENCE OF VITAMIN A DEFICIENCY, SCLERAL MELANOCYTOSIS, TOOTH DECAY AND SKIN INFECTION AMONG RURAL PRESCHOOL CHILDREN IN MULSHI TEHSIL, M/S, INDIA

SHARAD VITTHAL GIRAMKAR^{1*}

¹Department of Zoology, PDEA's Annasaheb Magar College, Hadapsar, Pune-28, M/S, India.

AUTHOR'S CONTRIBUTION

The sole author designed, analysed, interpreted and prepared the manuscript.

Received: 17 May 2020

Accepted: 24 July 2020

Published: 31 July 2020

Original Research Article

ABSTRACT

In present study, a village survey was carried out in rural areas of Mulshi Tehsil with the aim of assessing health related problems among the rural preschool children. Clinical examinations were carried out on 527 preschool children for various health issues. Their data was collected and analyzed to find the prevalence of Vitamin A Deficiency (VAD) and other common health issues like tooth decay, skin diseases, etc. These health issues might be due to illiteracy about hygiene, sanitation, exposure to humid atmosphere due to heavy rainfall in the study area, consumption of unfiltered borewell water for drinking, etc. The high humidity and improper sanitation leads to growth of harmful bacteria, viruses, fungi and/or other microbes. The present survey revealed 12.3% prevalence of VAD which includes 2% Night blindness, 2.5% xerophthalmia, 4% Bitot spots and 3.8% conjunctival xerosis among these preschool children. The other health issues observed among were 4.5% scleral melanocytosis, 2.7% tooth decay and 5.3% skin diseases.

Keywords: Preschool children; vitamin a deficiency; bitot spots; scleral melanocytosis; tooth decay; skin diseases.

1. INTRODUCTION

About 1/3rd of the world's preschool children are estimated to be vitamin A deficient with highest prevalence (44-50%) being reported in regions of South-East Asia and Africa [1]. Vitamin A Deficiency is still a major nutritional concern among the lower-income countries. This deficiency leads to xerophthalmia ranging from milder stages of night blindness and Bitot's spots to severe corneal xerosis or sometimes complete blindness [2]. This nutrient is required in adequate amounts for normal vision and immunity. Vitamin A also helps in cellular growth

and development [3]. VAD is widely prevalent in Africa, around 2% of preschool age children were found to be suffering from night blindness which is four times higher than proportion of South East Asia (0.5%) [2]. In Urban Central India it was found that 6.5% of children were suffering from xerophthalmia [4]. The National Oral Health Survey indicates that 51.9% of prevalence of dental issues was among children of 3 to 5 age in India [5] and 30% of total patients having skin diseases were children of the pediatric age group [6]. Hence, there was an urgent need to carry out a survey of children in rural areas in Maharashtra regarding the same.

*Corresponding author: Email: sharadgiramkar2@gmail.com;

2. METHODOLOGY

A village survey was conducted from February 2019 to January 2020. Survey was carried out in and around a 15 km hilly region (18°33'38"N 73°31'17"E) of Mulshi Tehsil, M/S, India. Survey was conducted with the aim of assessing health related problems among the rural preschool children of 3 to 6 years age group. Sub-clinical examinations of 527 preschool children were carried out by trained surveyors. Parameters considered for the survey were presence of vitamin A deficiency (xerophthalmia, Bitot's spot, night blindness, conjunctival xerosis etc.), scleral melanocytosis, tooth decay and skin infections etc. Photographs are taken with Sony cyber-shot DSC-W230 12 MP Digital Camera with 4x Optical Zoom. Guidelines provided by WHO were followed during the study. Data was collected and analyzed with Microsoft Excel 2007.

3. RESULTS

Clinical examination was carried out on 527 preschool children of age group 3 to 6 years. Vitamin A deficiency (xerophthalmia, night blindness, Bitot spot, conjunctival xerosis), scleral melanocytosis, tooth decay and skin diseases were examined during the study.

Plate 1. Vitamin A deficiency (VAD): The survey revealed 12.3 % prevalence of VAD which included 2.5% xerophthalmia, 2% night blindness, 4% Bitot's spots and 3.8% conjunctival xerosis

Plate-2: Scleral Melanocytosis (4.5%):

Plate-3. Tooth decay (2.7%):

Plate-4. Skin diseases (5.3%):

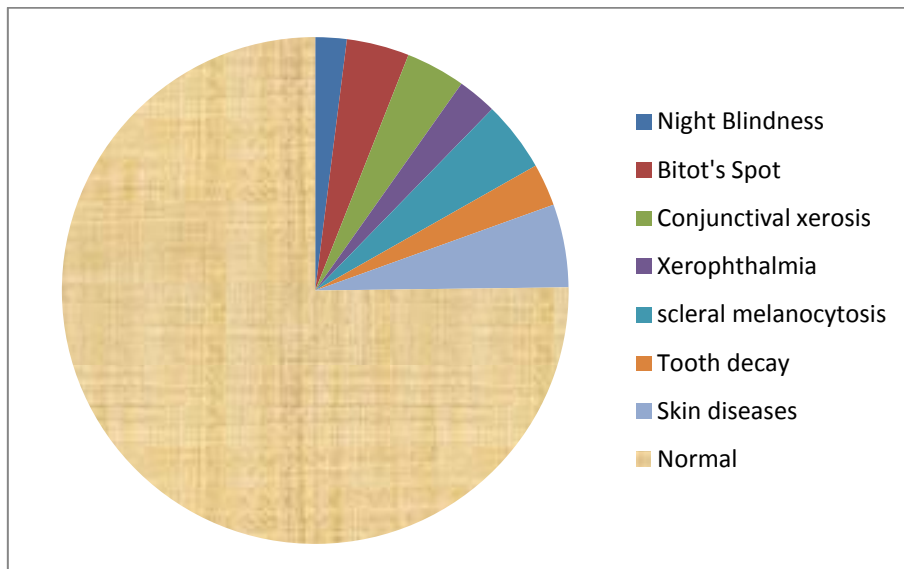


Chart 1. Prevalence of VAD, scleral melanocytosis, tooth decay and skin infection among rural preschool children

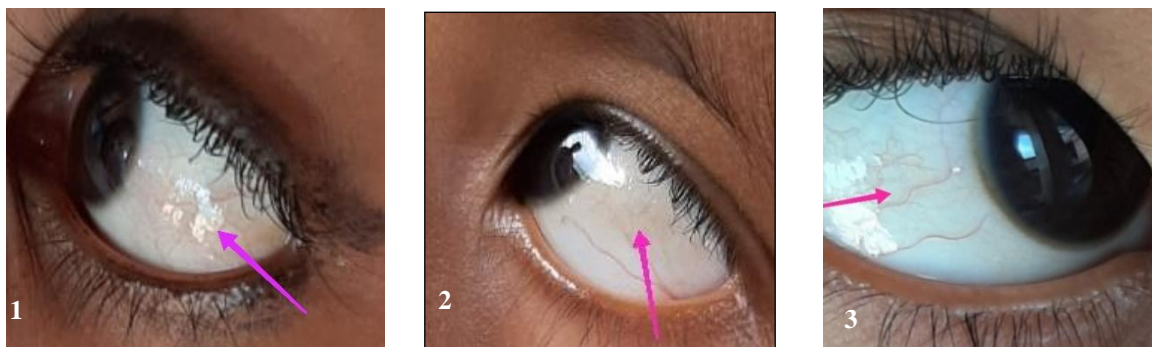


Plate 1. Pink arrows in above images indicate that Bitot's spots were observed in the survey

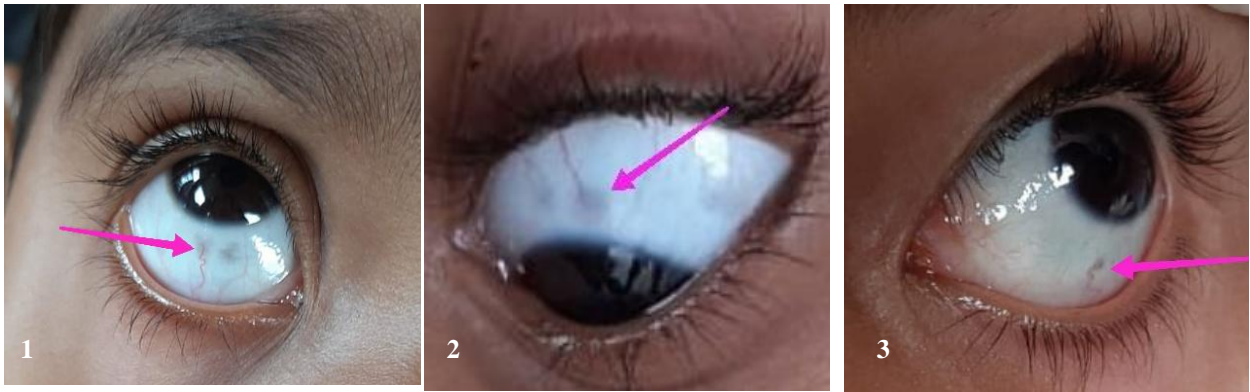


Plate 2. Pink arrows in images 1 to 3 indicate that scleral melanocytosis was observed in the survey

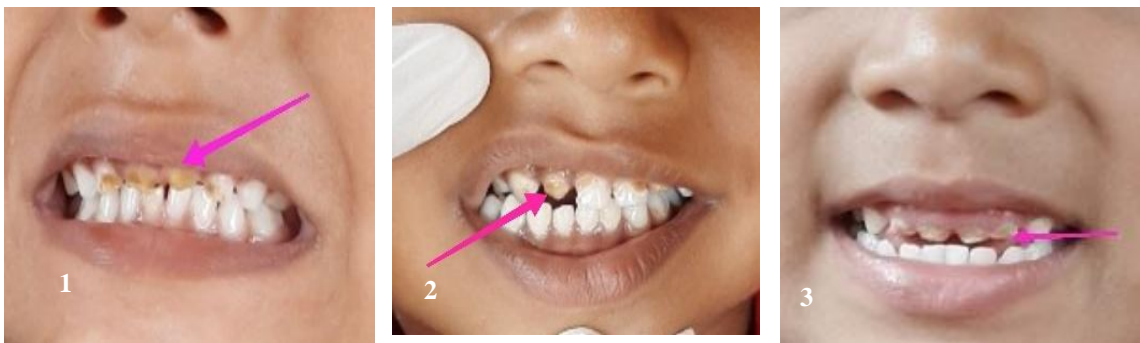

Plate 3. Pink arrows in images 1 to 3 indicate tooth decay was observed in the survey

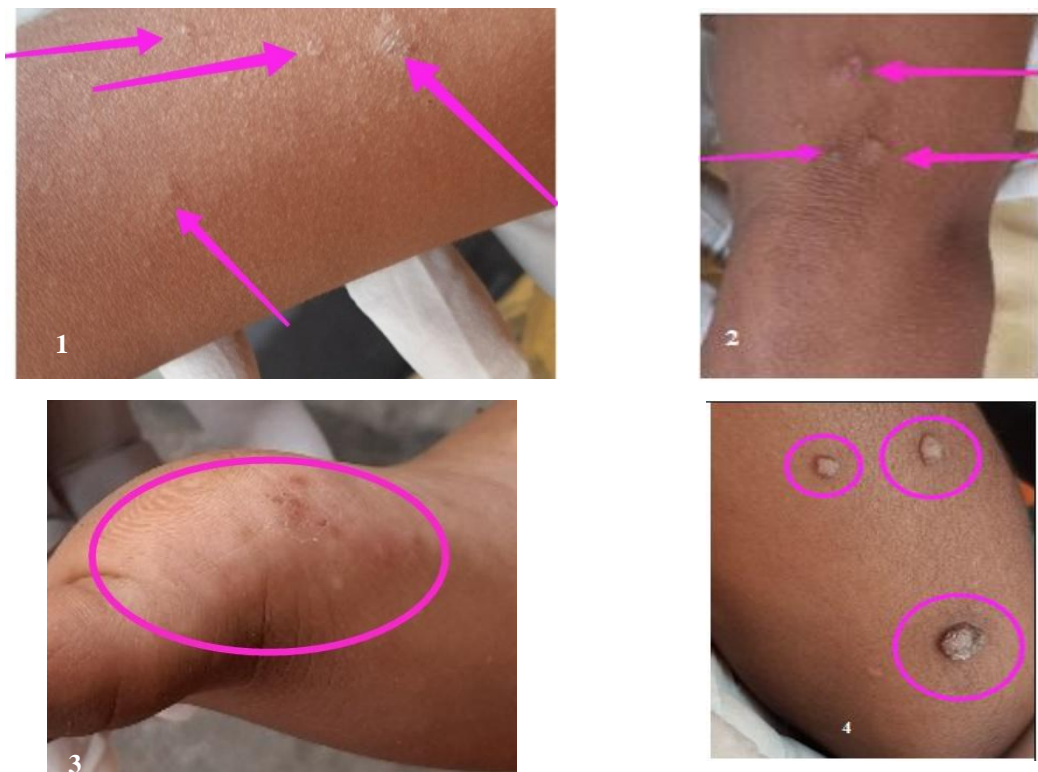


Plate 4. Pink arrows and pink circles in images 1 to 4 indicate that skin diseases were observed on foot and legs in the survey

4. DISCUSSION

This article reported a prevalence of diseases such as Bitot's spot, conjunctival xerosis, night blindness and xerophthalmia. These symptoms are the sign of VAD [7,8]. Hence, the preschool children in this area have a Vitamin A Deficiency. Therefore, it is believed that many other nutritional deficiencies might also be present in the study area. Many nutritionists believed that VAD has declined considerably in India [9] but the present study also indicates Vitamin A deficiency among the preschool children. Vitamin A is required for epithelial development. Deficiency of vitamin A causes Bitot's spots which may be a replacement of conjunctival epithelium to keratin layer. If VAD is removed, tissues return to their normal pattern [10].

A black or grey-blue pigmentation in the white portion of the eyes with normal vision was recorded in the present study. The grayish areas of pigmentation were determined to be scleral melanocytosis. Scleral melanocytosis is a common pediatric condition characterized by development of gray-blue pigmentation in the scleral tissues of the eyes. Histological examination show bipolar and multipolar dendritic melanocytes in the sclera of the eye, it may be associated with benign conditions [11,12].

It was observed that 2.7% of preschool children were having tooth decay in upper incisors and canines. It might be due to daily consumption of milk and sugar, chewing sweet candies and improper brushing of teeth. Negligence in brushing of teeth causes regular bacterial growth and it leads to tooth decay. It was also observed that drinking water source for preschool children was a bore well. There is an immediate need of detailed clinical analysis of drinking water resources present in the study area.

Present study revealed that 5.3% of the preschool children were affected by skin infections. Fungal skin infections were commonly found in the study area followed by bacterial and viral infections. It may be due to the presence of a humid atmosphere (Avg. humidity reported was 87%) in the study area. This humid atmosphere allows the microbial growth on walls of school and houses. These microbes may cause severe skin infections [13]. Vaccination is an excellent option for protection from these microbes [14]. It was also observed that children below ten years of age were the primary victims of the Hand, Foot and Mouth diseases (HFMD). It was noted that children were regularly suffering from mild fever and skin problems.

5. CONCLUSION

The results obtained in present study indicate that among the 527 preschool children, 12.3% of them are suffering from Vitamin-A Deficiency (VAD) with symptoms of night blindness (2%), xerophthalmia (2.5%), Bitot's Spots (4%) and conjunctival xerosis (3.8%). The other health issues found were sclera melanocytosis (4.5%), tooth decay (2.7%) and skin diseases (5.3%). As per the results, there is an urgent need to create awareness among the parents and children about the importance of Vitamin A, balanced diet, hygiene and timely vaccination. As water is a fundamental need, it is necessary to provide them clean and safe water for drinking, cooking and other purposes. Scleral melanocytosis is a common pediatric condition observed in the study area. Hence, there is a need to conduct a detailed histological examination for the same. It is necessary to create awareness of oral hygiene among parents and children to prevent tooth decay. Skin diseases are a common issue among the preschool children as they are exposed to a humid atmosphere. It is necessary to maintain proper ventilation in schools and houses of the study area.

ACKNOWLEDGEMENTS

The author wishes to thank Dr. Ramchandra P. Babar M.D. Ph.D. (AY.PAED) Pediatrician and Neonatologist, Kashyap Child Clinic, Kharadi, Pune for critical suggestions during necessary discussions. Thanks to Mr. Nikhil Giramkar for data analysis. Thanks to all students who have offered every possible support during the village survey.

COMPETING INTERESTS

Author has declared that no competing interests exist.

REFERENCES

1. WHO. World Health Organization (WHO). Global prevalence of vitamin A deficiency in populations at risk 1995-2005. WHO Global Database on vitamin A deficiency. Geneva: WHO; 2009.
2. Zekariyas Sahile et.al. Prevalence of Vitamin A Deficiency among Preschool Children in Ethiopia: A systematic review and meta-analysis. *BioMed Research International*. 2020. [Article ID 8032894:1-12]
3. Amare Tariku et.al. Vitamin-A deficiency and its determinants among preschool children: A community based cross-sectional study in Ethiopia. *BMC Res Notes*. 2016;9:323. DOI: 10.1186/s13104-016-2134-z, pp1-8
4. Dr. Sinha et al. Vitamin A Deficiency in schoolchildren in urban Central India:

- The Central India Children Eye Study. *Arch Ophthalmol.* 2011;129(8):1095-1096.
5. Patil Snehal et al. Prevalence of untreated dental caries among the preschool children of Western Maharashtra. *Journal of Dentistry and Oral Hygiene.* 2015;7(11):175-178.
 6. GM Sangameshwara et.al. Clinical study of cutaneous infection in children: Changing trends. *Indian Journal of Paediatric Dermatology.* 2015;16(3):136-138.
 7. D.W. Khandait et.al. Vitamin A intake and xerophthalmia among Indian children. *Public Health.* 1999;113(2):69-72.
 8. NMB. National Nutrition Monitoring Bureau (NNMB). Prevalence of micronutrient deficiencies. Hyderabad, India: National Institute of Nutrition; 2003.
 9. Arlappa N. Vitamin A deficiency is still a public health problem in India. *Indian Pediatrics.* 2011;48:853-854.
 10. Ranjeeta Chatterjee. Prevalence of vitamin A deficiency in primary school children of Taluka Maval, District Pune of India. *Int.j. curr.res. aca Rev.* 2014;2(1):25-29.
 11. Leung AKC, Robson WLM. Scleral Melanocytosis. In: F. (eds) *Encyclopedia of molecular mechanism of Disease.* Springer, Berlin, Heidelberg; 2009.
 12. Leung AKC. A spot in the eye. *Am Fam Physician.* 1999;59(1):163-164.
 13. Paller AS, Mancini AJ. *Hurwitz clinical pediatric dermatology: A Textbook of Skin Disorders of Childhood and Adolescence;* 4th ed. Philadelphia, PA: Elsevier; 2011.
 14. Nilendu Sarma. Hand, foot and mouth disease: Current scenario and Indian perspective. *Indian Journal of Dermatology, Venereology and Leprology.* 2019;79(2):165-175.