



International Journal of Medical and Pharmaceutical Case Reports

11(4): 1-6, 2018; Article no.IJMPCR.47307
ISSN: 2394-109X, NLM ID: 101648033

Endovascular Treatment for a Femoral Arteriovenous Fistula after Removal of a Hemodialysis Catheter

Lam Thao Cuong¹, Ho Tat Bang^{1*} and Nguyen Duy Tan²

¹*Ho Chi Minh City University of Medicine and Pharmacy, 217 Hong Bang street, District 5,
Ho Chi Minh City, Viet Nam.*

²*Department of Vascular Surgery, Cho Ray Hospital, 201 Nguyen Chi Thanh street, District 5,
Ho Chi Minh City, Viet Nam.*

Authors' contributions

This work was carried out in collaboration between all authors. Author NDT was a main surgeon, reviewed the drafted manuscript. Authors LTC and HTB wrote the first draft of the manuscript, managed the analyses of the study, managed the literature searches, followed up the patients during the period. All authors read and approved the final manuscript.

Article Information

DOI: 10.9734/IJMPCR/2018/V11i430092

Editor(s):

(1) Dr. Claudio Piras, Department of Surgery, Universidade Federal do Espírito Santo, Brazil.

Reviewers:

(1) Serghei Covantev, State University of Medicine and Pharmacy N. Testemitanu, Moldova.

(2) Dr. Roberto J. Barone, University of Buenos Aires, Argentina.

(3) Saptarshi Biswas, Forbes Hospital, Allegheny Health Network, Pennsylvania, USA.

Complete Peer review History: <http://www.sdiarticle3.com/review-history/47307>

Case Study

Received 28 October 2018
Accepted 17 February 2019
Published 25 February 2019

ABSTRACT

Double-lumen catheters are commonly utilized to acquire temporary access for hemodialysis in patients suffering from acute renal failure. There are many complications related to catheter puncture. An arteriovenous fistula (AVF) is rare but occasionally fatal. This case report presents a female patient, 49 years old with a post-catheterization AVF between the femoral common artery and femoral vein, which was successfully treated with a peripheral cover stent placement. A four-week clinical follow-up showed the patient's condition had significantly improved.

Keywords: *Arteriovenous fistula; hemodialysis; endovascular.*

*Corresponding author: E-mail: hotatbang@gmail.com;

ABBREVIATIONS

AVF : Arteriovenous Fistula
 HD : Hemodialysis
 CT : Computed Tomography

1. INTRODUCTION

An arteriovenous fistula (AVF) is defined as an abnormal connection between an artery and a vein. Double-lumen catheters have been commonly utilized to acquire temporary access for hemodialysis in patients suffering from acute renal failure [1]. Potential complications of catheter insertion include puncture site hemorrhage, pseudoaneurysm formation, vessel dissection, distal thrombosis, and arteriovenous fistulas formation [2]. An iatrogenic AVF is a rare but severe complication, that can cause congestive cardiac failure and reduced circulation to the limbs [3]. These days, with the development of interventional procedures, covered stent placement with the endovascular technique for these lesions represents an appealing treatment alternative because it is not only minimally invasive but also requires less hospitalization and recovery time compared to open surgical repair [4]. Herein, we present a female patient, 49 years old with a post-catheterization AVF between the femoral common artery and femoral vein, which was successfully treated with a peripheral cover stent placement. A four-week clinical follow-up showed the patient's condition had significantly improved.

2. CASE PRESENTATION

2.1 Past Medical History

A 49-year-old female patient with a 9-year history of chronic renal failure with periodic hemodialysis (HD), was admitted to a local hospital because of high fever and widespread infection in the right leg. 3 years prior, when unable to gain regular vascular access for hemodialysis, a double-lumen catheter was inserted into the right femoral vein to obtain temporary access to circulation for hemodialysis without ultrasound guidance. Two hours after completion of the first HD, a wide hematoma was observed around the puncture site. Three months after the catheter removal, she was readmitted to the local hospital because of right lower limb swelling and calf pain. At this hospital, she was confirmed to have a right femoral AVF and underwent an open surgery for vascular repair. Unfortunately, the operation was unsuccessful. One year later, the

patient was admitted to the same hospital for AVF closure, but it failed and the Guide Wire was reportedly dropped in the common iliac vein to vena cava and right atrium. After this incident, the patient refused all future surgical proposals. 10 days ago, she had a fever, swelling and a lot of ulcers in the right leg. She was diagnosed with sepsis and received active treatment with antibiotics. Once her condition was stabilized, she was transferred to the Cho Ray Hospital.

2.2 Physical Findings

- Vital signs: Pulse rate 92 beats per minute, body temperature 39 degrees C, respiratory rate 25 breaths per minute, blood pressure 120/90 mmHg.
- The patient was fatigued, with pallor skin.
- Physical examination revealed swelling from the groin to the lower leg, cellulitis in the calf and ulcers of the toes. A bruit was heard on auscultation and a fluid thrill was felt at the right inguinal area. The leg circumference was compared with the unaffected side, as shown in Table 1.

Table 1. The comparison between left and right leg circumference

Position	Right leg	Left leg
Femoral circumference	83 mm	42 mm
Calf circumference	45 mm	33 mm

2.3 Imaging Diagnosis

- A Doppler ultrasound revealed an AVF between the right common femoral artery and the right femoral vein, with a hole of 4mm in diameter (Fig. 1). In addition, the ultrasound findings also detected a hyperechoic rod-shaped structure in the common iliac vein extending to the vena cava.
- Computed Tomography angiography detected an AVF between the right common femoral artery and the right femoral vein, with dilated circulatory vessels around the inguinal, and collateral circulation (Fig. 2).

2.4 Treatment and Follow up

Given the severity of the patient's condition, the high risk of anesthesia and failure in open surgery, we decided to insert a cover stent into the common femoral artery to close the AVF under local anesthesia and the puncture site in

the left common femoral artery, to avoid entering the infected area in the right groin.

The procedure was performed in the digital subtraction angiography unit. A vascular ultrasound probe (5 Hz- GE Healthcare Ultrasound) was used to locate the left common femoral artery and arterial access obtained under direct ultrasound guidance via a sheath 6 French introducer (*Radifocus® Introducer II Transradial Kit*). A Guidewire (0.035 Inch X 150 CM *Terumo Guide Wire*) was used to approach abdominal aorta. Then, this Guidewire was advanced through a 5F Cobra catheter (*Boston Scientific*) into the right common femoral artery. The Cobra catheter was removed and replaced by a Pigtail catheter (*Boston Scientific*). We injected contrast agent via Pigtail catheter to determine the fistula and the right common femoral vein appeared straightway after injecting contrast agent (Fig. 3A). We decided to insert a with a 6 mm×57 mm cover stent (*BeGraft BENTLEY INNOMED stent*) from the common femoral artery through the fistula to the femoral bifurcation. On the image after the intervention, it was clear that the AVF was completely closed (Fig. 3B).

About the Guidewire, which was reportedly dropped in the common iliac vein to vena cava and right atrium, we did not remove. It was there for 2 years, so it would be difficult to remove because it was attached to the vascular endothelium. When we discussed with the patient, she refused all interference on it.

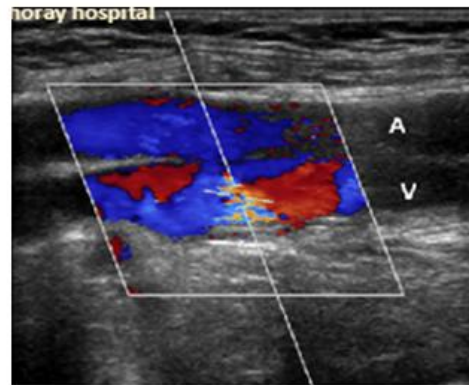


Fig. 1. Ultrasound findings showed a fistula between the common femoral artery and the femoral vein

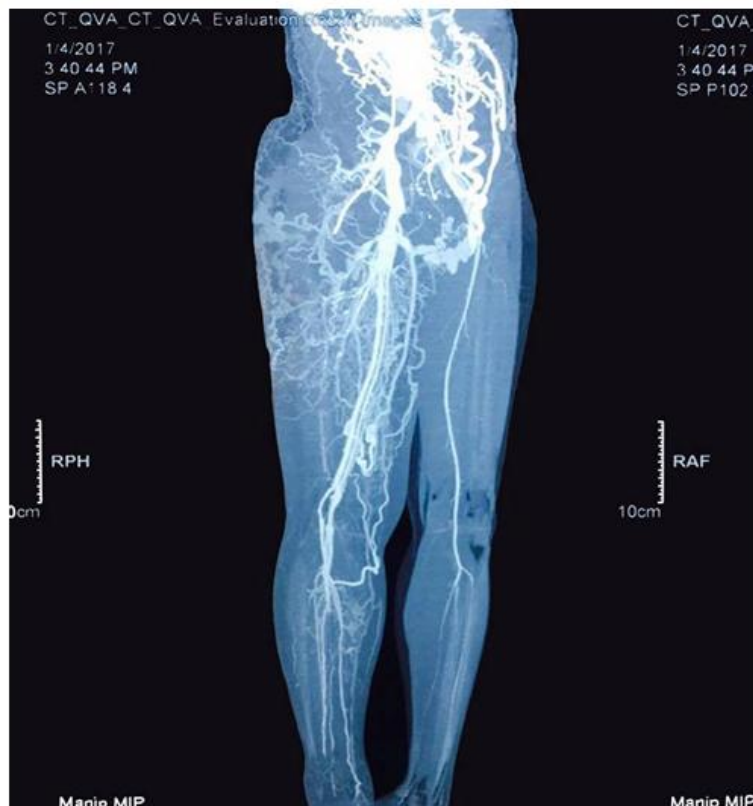


Fig. 2. CT angiography figure

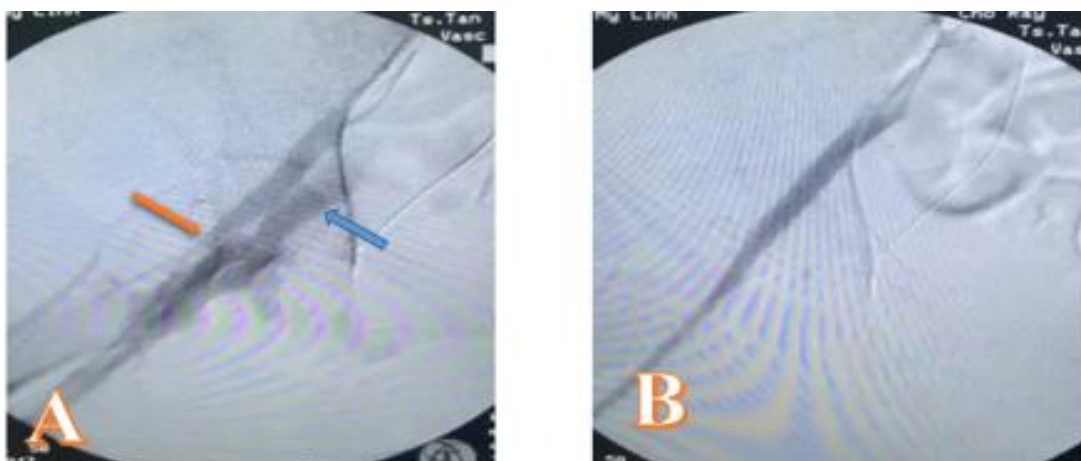


Fig. 3. The difference between before (A) and after (B) inserting the cover stent
Orange arrow: the fistula, Blue arrow arrow: Femoral vein appeared straightway after injecting contrast agent

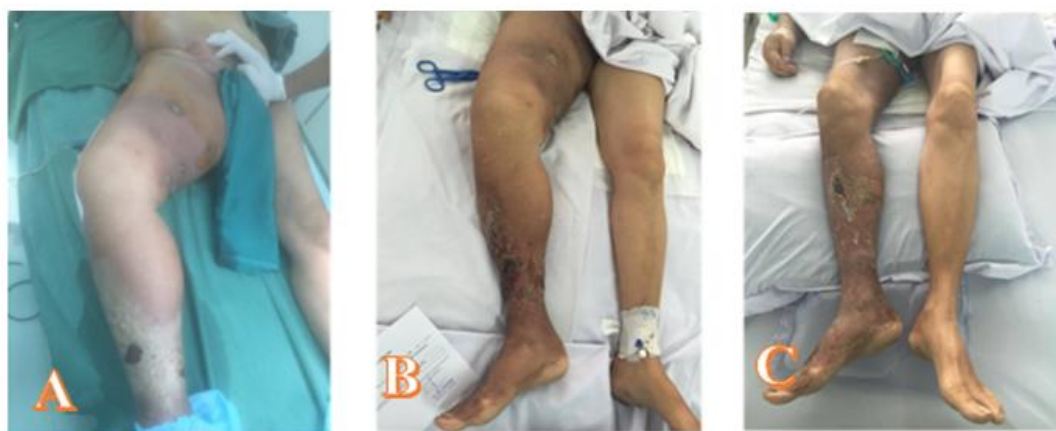

Fig. 4. The leg condition pre-intervention (A), 1 week (B) and 3 weeks (C) post- intervention

The patient was followed up in the vascular department before being transferred to the internal department, and was discharged 9 days after the intervention. The condition of the right leg improved, and the swelling decreased significantly (as seen in Table 2 and Fig. 4).

3. DISCUSSION

An AVF is an irregular connection between an artery and a vein, and the incidence of post-catheterisation AVFs range from 0.006 to 0.86% [5]. AVF as a complication of dual-lumen HD catheter insertion has been described in literature around the world. Although it is rare, when it occurs it can cause complications such as chronic limb swelling and high output cardiac failure [6,7]. To reduce the risk, ultrasound is recommended. Many reports indicate that

ultrasound guidance is superior to make a landmark, and ultrasound guidance is of particular value in increasing “first-pass” rates and reducing the risk of hematoma formation and other complications related to catheter insertion [8]. In this case, no ultrasound-guidance was used for double-catheter insertion. As a result, the blind puncture caused trauma on blood vessels leading to a hematoma and AVF formation. The existence of the AVF led to significant shunting of blood from the femoral artery to the venous system. The increased venous return eventually lead to the development of a high-output cardiac failure state, and the blood pressure in the lower vein system caused swelling and ulcers. As a result, the patient presented with swelling and infectious ulcers. Moreover, the failure of the open surgical repair and endovascular intervention made her refuse

all subsequent surgical interventions, and for this reason the condition of her right leg worsened with widespread infection and sepsis.

Table 2. The change in circumference between 7 days and 21 days follow up

Position	7 days	21 days
Right femoral circumference	65 mm	55 mm
Calf circumference	38 mm	31 mm

Different treatment modalities are available for iatrogenic AVFs, including open surgical repair and percutaneous endovascular management. In this case, the patient's previous open repair surgery had failed and her medical state was serious. Endovascular repair was therefore a safer option as it has a lower risk of surgical complications and mortality compared to open conventional repair. Furthermore, with the widespread infection, open surgery was not a suitable treatment method.

After inserting a cover stent via endovascular intervention, the angiography figures confirmed that the fistula was closed, and there was no blood flow from the femoral artery to the venous system. The condition of the right leg was notably improved in the follow up period.

An AVF following insertion of a double-catheter is rare but can cause serious problems. We would advocate for routine use of ultrasound-guided arterial punctures to minimise the risk of femoral AVF formation as well as other complications [9].

4. CONCLUSION

Femoral venous catheterization is frequently used to obtain temporary access to circulation in patients requiring emergency HD. Iatrogenic AVFs are rare but occasionally fatal. It is recommended that ultrasound guidance be widely used for catheter insertion to avoid inadvertent arterial puncture. If iatrogenic AVFs are detected early and lesions are suitable for endovascular repair, cover-stent should be considered as an alternative treatment modality.

ACKNOWLEDGEMENT

We thank our colleagues from Cardiovascular Centre of Cho Ray Hospital who provided insight and expertise in taking care of this patient. We would also like to show our gratitude to Ms. Elanie Marks (World Health Organization) for

comments and revisions that greatly improved the manuscript.

CONSENT AND ETHICAL APPROVAL

As per university standard guidelines, participant consent and ethical approval has been collected and retained by the authors.

COMPETING INTERESTS

Authors have declared that no competing interests exist.

REFERENCES

- Lee CH. Stent graft repair of iatrogenic femoral arteriovenous fistula with acute bleeding after hemodialysis catheter insertion. *Hemodialysis International*. 2016; 20:497-500.
- Kelm M, Perings SM, Jax T, Lauer T, Schoebel FC, Heintzen MP, Perings C, Strauer BE. Incidence and clinical outcome of iatrogenic femoral arteriovenous fistulas: Implications for risk stratification and treatment. *Journal of the American College of Cardiology*. 2002;40:291-297.
- Stolic R. Most Important chronic complications of arteriovenous fistulas for hemodialysis. *Medical Principles and Practice*. 2013;22:220-228.
- Lakhan SE, Kaplan A, Laird C, Leiter Y. The interventionalism of medicine: interventional radiology, cardiology, and neuroradiology. *International Archives of Medicine*. 2009;2:27-27.
- Porter J, Al-Jarrah Q, Richardson S. A case of femoral arteriovenous fistula causing high-output cardiac failure, originally misdiagnosed as chronic fatigue syndrome. *Case Reports in Vascular Medicine*. 2014;2014:510429-510429.
- Hüseyin S, Yüksel V, Güçlü O, Yılmaztepe M, Canbaz S. A rare etiology of heart failure: Traumatic arteriovenous fistula due to stab injury 17 years ago. *Balkan Medical Journal*. 2015;32:309-311.
- Thavarajan D, Bakran A. Iatrogenic arteriovenous fistula in the groin presenting as cardiac failure. *NDT Plus*. 2009;2:46-48.
- III. NKF-K/DOQI Clinical practice guidelines for vascular access: Update 2000. *American Journal of Kidney Diseases*. 2001;37:S137-S181.

9. Kurisu K, Osanai T, Kazumata K, Nakayama N, Abumiya T, Shichinohe H, Shimoda Y, Houkin K: Ultrasound-guided Femoral Artery Access for Minimally Invasive Neuro-intervention and Risk Factors for Access Site Hematoma. *Neurologia medico-chirurgica* 2016, 56:745-752.

© 2018 Cuong et al.; This is an Open Access article distributed under the terms of the Creative Commons Attribution License (<http://creativecommons.org/licenses/by/4.0>), which permits unrestricted use, distribution, and reproduction in any medium, provided the original work is properly cited.

Peer-review history:
The peer review history for this paper can be accessed here:
<http://www.sdiarticle3.com/review-history/47307>