

Chromobacterium violaceum Related Urinary Tract Infection: A Case Report

IMOLA JAMIR¹, LAKSHMI SHANMUGAM², GOPINATH KARUPPIAH³, STALIN VISWANATHAN⁴, JHARNA MANDAL⁵



ABSTRACT

Chromobacterium violaceum (*C. violaceum*) is a motile, gram-negative bacilli found in water and moist soil. Infections due to *C. violaceum* are uncommon but have a significant mortality rate (upto 80%) due to their tendency for haematogenous dissemination resulting in sepsis. The organism has been reported to cause skin and soft tissue infections, diarrhoea, bacteremia, and visceral abscess; Urinary Tract Infection (UTI) is rarely seen. Here, a 41-year-old male diabetic who presented with fever, altered sensorium and burning micturition caused by *C. violaceum* is presented. Initial investigations revealed an increased Random Blood Sugar (RBS) level, high anion gap metabolic acidosis with normal renal and liver function (except for hypoalbuminemia). Diabetic ketoacidosis, probable meningitis and urosepsis were considered as differential diagnosis. On culture of urine sample, *C. violaceum* was isolated which was susceptible to all the antibiotics tested except amikacin. Blood culture was reported as sterile. Patient was successfully treated with susceptible antibiotic (ciprofloxacin) and repeat culture of urine was also sterile. Early diagnosis and adequate treatment is necessary to reduce the risk of progression to fatal infection.

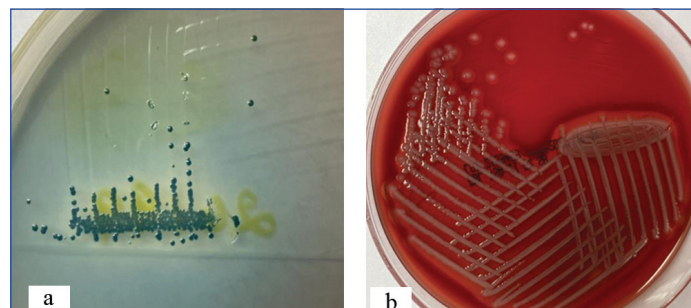
Keywords: Gram-negative bacilli, Sepsism, Violet colonies

CASE REPORT

A 41-year-old male farmer presented with complaints of intermittent high-grade fever for five days, without chills and rigours, altered sensorium in the form of decreased responsiveness, inability to walk or sit by himself, and reduced speech for five days. Additionally, he complained of burning micturition and difficulty getting up from bed on his own. There was no history of pain abdomen or dysuria. He had type 2 Diabetes Mellitus (DM) for the past 15 years and has been poorly compliant with medications for the last two months. On admission, his RBS level was 460 mg/dL and Arterial Blood Gas (ABG) was showing high anion gap metabolic acidosis. Due to festivities in his native village, he had been consuming alcohol for one week before admission.

Examination revealed a patient with altered sensorium, moving all limbs with stable vitals and herpes labialis. Diabetic ketoacidosis, probable meningitis and urosepsis were considered. He was empirically initiated on ceftriaxone (2 g i.v. in 100 mL Normal Saline (NS) q24H) (since the culture reports of urine and blood samples were pending). Serum electrolytes, renal and liver function were normal except for hypoalbuminemia (2.8 g/dL); serum osmolality was 317 mmol/L. His total leukocyte count was $13 \times 10^9/L$, with 84% neutrophilia. His lipase was elevated at 260 U/L (<60), and his HbA1c was 10.3%. A urine sample was taken aseptically from the hub of the urinary catheter and sent to the microbiology laboratory. Microscopy revealed occasional pus cells without RBCs or casts. The urine sample was plated on Cysteine Lactose Electrolyte Deficient (CLED) agar using a calibrated 1 μ L loop (without intermittent heating) and incubated overnight at 37°C under aerobic conditions. On CLED, a single type of pigmented (non diffusible) violet colonies was observed; ~1-2 mm, circular, smooth, low convex, with a count of 10^4 CFU (colony forming unit)/mL urine [Table/Fig-1a]. The isolate was identified as *C. violaceum* by Matrix Assisted Laser Desorption Ionisation-Time of Flight Mass Spectrophotometry (MALDI-TOF MS; VITEK2, BioMérieux), with 99.9% confidence interval. Subculture was done from CLED onto 5% Sheep Blood Agar (SBA) (HiMedia, Mumbai, India) and Nutrient Agar (NA); on SBA, growth was observed as ~2-3 mm, grey-moist, low convex, smooth colonies with beta-haemolysis [Table/Fig-1b]. On NA, growth was seen as ~2-3 mm, low convex colonies but pigment production was not observed on SBA or NA subculture

plates. Since disc diffusion criteria are not available for this organism, the Antimicrobial Susceptibility Test (AST) was performed by using Vitek, BioMérieux, France. The isolate was resistant to amikacin and susceptible to ceftriaxone, ceftazidime, ciprofloxacin, cefoperazone-sulbactam, piperacillin-tazobactam, and meropenem. The organism was considered a significant pathogen as the patient had poorly controlled diabetes, mild pancreatitis, and possible rhabdomyolysis, and he presented with fever and urologic symptoms.



[Table/Fig-1]: a) Non diffusible, pigmented violet colonies on CLED; 1b) Haemolytic colonies on 5% Sheep Blood Agar (SBA).

His sensorium improved within 24 hours of admission, and he began eating within 48 hours. Lumbar puncture was initially planned in view of altered sensorium and suspected meningitis but deferred later due to improvement in sensorium. Seventy-two hours later, his limb power was only 4/5 in all limbs. Probable alcohol-related rhabdomyolysis was considered; Creatine Kinase (CK)-total was normal, and urine myoglobin was negative. On the fifth day of admission, he complained of nasal pain. Examination showed blackish crusts on his right nostril; Ear, Nose and Throat (ENT) examination and subsequent microbiology smear showed infection with *Aspergillus*. Contrast computed tomography of the sinuses showed no bony erosions or angioinvasion. He was initiated on Inj. voriconazole (200 mg i.v. q12H) and his symptoms began improving. After three days of Inj. voriconazole, switch was made to oral therapy (Tablet voriconazole 200 mg BD). Moreover, based on the AST report, ceftriaxone was discontinued and patient was started on Inj. ciprofloxacin (500 mg i.v. BD) on fifth day of admission. After seven days of receiving Inj. ciprofloxacin, transition was made to oral therapy (Tablet ciprofloxacin 500 mg BD). Repeat urine culture did not isolate the same organism. Of note, paired

blood culture samples were also collected in adult BacT/ALERT bottles and incubated aerobically at 37°C in the BacT/Alert Virtuo system (BioMérieux, France). It was reported as sterile after five days of incubation.

Patient improved symptomatically and was discharged after 16 days of hospital stay and advised to continue oral voriconazole (200 mg BD) for 21 days and oral ciprofloxacin (500 mg BD) for 14 days. He was also advised to follow-up in Medicine Outpatient Department (OPD) and ENT OPD after two weeks.

DISCUSSION

C. violaceum is a gram-negative, facultatively anaerobic, oxidase-positive bacilli found in water (usually stagnant) and soil in tropical and subtropical areas [1]. Temperatures between 20°C to 37°C are ideal for its growth and infections occur commonly in tropical areas and in summer months [2]. On solid culture media, most strains produce a violet-black pigment, violacein, which protects the bacilli from oxidative damage induced by the host to infection. However, pigment may be lost on subculture or treatment with antibiotics [2]. Infection by this organism can occur by exposure to the bacilli following skin trauma or consumption of contaminated water and food [3]. Predisposing factors for infection with *C. violaceum* includes glucose-6-phosphate deficiency, chronic granulomatous disease and immunocompromised individuals [4]. Farmers, like index patient, may have a higher risk of infection due to exposure of injury to soil and sluggish farmland water, leading to skin infections and septicemia [4-6]. Current patient did not have history of skin injury or infection however he was catheterised at admission which may be a factor for the introduction of the organism in the urinary tract.

The organism has also been reported to cause pneumonia, visceral abscesses (lungs, spleen), meningitis, endocarditis, Gastrointestinal (GI) tract infections, although infection of the urinary tract is rare [1-3,7]. Few reports of *C. violaceum* associated UTIs have been described, mostly in patients with underlying urologic abnormalities (neurogenic bladder, chronic kidney disease) and in catheterised individuals [1-3,7,8]. Blood culture in these patients was negative and all cases had good clinical improvement following treatment, similar to index patient. The organism has high tendency for haematogenous spread and infection can rapidly progress to sepsis and cause significant mortality (upto 80%) [7,9]. The organism is considered an opportunistic human pathogen; however, cases have been reported in non immunocompromised patients, too [9]. In this case, the patient presented with fever and urologic symptoms, as well as poorly controlled diabetes, mild pancreatitis and possible rhabdomyolysis, therefore the isolate was considered significant.

The information on antimicrobial susceptibility pattern of *C. violaceum* is limited due to lack of reports from clinical specimens. However, according to reports available, most strains of *C.*

violaceum are resistant to penicillins and cephalosporins whereas carbapenems (e.g., imipenem), aminoglycosides (e.g., gentamicin) and Fluoroquinolones (FQs) show good activity against the organism. Ciprofloxacin is considered the most effective antimicrobial agent for treatment [2,7,10]. The AST pattern of the *C. violaceum* isolates from India studied so far have shown them to be completely susceptible to ciprofloxacin and cotrimoxazole [11]. Hence, patient was started on ciprofloxacin therapy following the AST report. In index case, the isolate was resistant to amikacin and susceptible to all the other antimicrobial agents tested. Extended treatment for upto six weeks may be recommended in some cases, as relapse has been noted [9]. It is, thus, emphasised that early diagnosis and appropriate treatment with antimicrobial agents prevent the development of localised infections to sepsis.

CONCLUSION(S)

UTI by *C. violaceum* is uncommon but the organism is considered an emerging pathogen in light of climate changes. The organism also has tendency for haematogenous dissemination hence prompt and adequate treatment is necessary.

REFERENCES

- [1] Laghu U, Yanagawa M, Morimoto K, Dhoubhadel BG. *Chromobacterium violaceum*: A rare cause of urinary tract infection. Case Reports in Infectious Diseases. 2021;2021:5840899.
- [2] Kaniyarakkal V, Orvankundil S, Lalitha SK, Thazhethakandi R, Thottathil J. *Chromobacterium violaceum* septicaemia and urinary tract infection: Case reports from a tertiary care hospital in South India. Case Reports in Infectious Diseases. 2016;2016:6795743.
- [3] Pant ND, Sharma M. Urinary tract infection caused by *Chromobacterium violaceum*. Int J Gen Med. 2015;8:293.
- [4] Mazumder R, Sadique T, Sen D, Mozumder P, Rahman T, Chowdhury A, et al. Agricultural injury-associated *Chromobacterium violaceum* infection in a Bangladeshi farmer. The American Journal of Tropical Medicine and Hygiene. 2020;103(3):1039.
- [5] Slesak G, Douangdala P, Inthalad S, Silisouk J, Vongsouvath M, Sengduangphachanh A, et al. Fatal *Chromobacterium violaceum* septicaemia in northern Laos, a modified oxidase test and post-mortem forensic family G6PD analysis. Annals of Clinical Microbiology and Antimicrobials. 2009;8(1):01-05.
- [6] Khadanga S, Karuna T, Dugar D, Satapathy SP. *Chromobacterium violaceum* -induced sepsis and multiorgan dysfunction, resembling melioidosis in an elderly diabetic patient: A case report with review of literature. Journal of Laboratory Physicians. 2017;9(04):325-28.
- [7] Pant ND, Acharya SP, Bhandari R, Yadav UN, Saru DB, Sharma M. Bacteremia and urinary tract infection caused by *Chromobacterium violaceum*: Case reports from a tertiary care hospital in Kathmandu, Nepal. Case Reports in Medicine. 2017;2017:7929671.
- [8] Mohan V, Rajan R, Haneefa S. *Chromobacterium violaceum* causing urinary tract infection: a case report. Journal of The Academy of Clinical Microbiologists. 2014;16(2):90.
- [9] Swain B, Otta S, Sahu KK, Panda K, Rout S. Urinary tract infection by *Chromobacterium violaceum*. J Clin Diag Res. 2014;8(8):DD01.
- [10] Sirinavin S, Techasaensiri C, Benjapornpitak S, Pornkul R, Vorachit M. Invasive *Chromobacterium violaceum* infection in children: Case report and review. The Pediatric Infectious Disease Journal. 2005;24(6):559-61.
- [11] Nayyar C, Sethi S, Vashishth R. Successful treatment of *Chromobacterium violaceum* in a north indian adult: A case report with review of literature. J Clin Diag Res. 2019;13(9):DD03-DD05.

PARTICULARS OF CONTRIBUTORS:

1. Junior Resident, Department of Microbiology, JIPMER, Puducherry, India.
2. Senior Resident, Department of Microbiology, JIPMER, Puducherry, India.
3. Junior Resident, Department of Medicine, JIPMER, Puducherry, India.
4. Additional Professor, Department of Medicine, JIPMER, Puducherry, India.
5. Professor, Department of Microbiology, JIPMER, Puducherry, India.

NAME, ADDRESS, E-MAIL ID OF THE CORRESPONDING AUTHOR:

Dr. Jharna Mandal,
Professor, Department of Microbiology, JIPMER, Puducherry-605006, India.
E-mail: drjharna@gmail.com

AUTHOR DECLARATION:

- Financial or Other Competing Interests: None
- Was informed consent obtained from the subjects involved in the study? Yes
- For any images presented appropriate consent has been obtained from the subjects. Yes

PLAGIARISM CHECKING METHODS: [Jan H et al.]

- Plagiarism X-checker: Oct 30, 2022
- Manual Googling: Mar 15, 2023
- iThenticate Software: Apr 27, 2023 (6%)

ETYMOLOGY: Author Origin

Date of Submission: Oct 29, 2022
Date of Peer Review: Dec 03, 2022
Date of Acceptance: Jan 27, 2023
Date of Publishing: May 01, 2023